

## CLINICAL INVESTIGATION

# Multicentric Assessment of Safety and Efficacy of Combinatorial Adjuvant Brain Metastasis Treatment by Intraoperative Radiation Therapy and Immunotherapy



Julian P. Layer, MD,<sup>\*,†</sup> Ehab Shiban, MD,<sup>‡</sup> Stefanie Brehmer, MD,<sup>§</sup> Christian D. Diehl, MD,<sup>||</sup> Douglas Guedes de Castro, MD,<sup>¶</sup> Motaz Hamed, MD,<sup>#</sup> Cas S. Dejonckheere, MD,<sup>\*</sup> Daniel T. Cifarelli, MD,<sup>\*\*</sup> Lea L. Friker, MD,<sup>††</sup> Ulrich Herrlinger, MD,<sup>‡‡</sup> Michael Hölzel, MD,<sup>†</sup> Hartmut Vatter, MD,<sup>#</sup> Matthias Schneider, MD,<sup>#</sup> Stephanie E. Combs, MD,<sup>||</sup> Leonard Christopher Schmeel, MD,<sup>\*</sup> Christopher P. Cifarelli, MD, PhD,<sup>\*\*</sup> Frank A. Giordano, MD,<sup>§§</sup> ||<sup>¶¶</sup> Gustavo R. Sarria, MD,<sup>\*</sup> and Klaus-Henning Kahl, MD<sup>##</sup>

<sup>\*</sup>Department of Radiation Oncology, University Hospital Bonn, Bonn, Germany; <sup>†</sup>Institute of Experimental Oncology, University Hospital Bonn, Bonn, Germany; <sup>‡</sup>Department of Neurosurgery, University Hospital Augsburg, Augsburg, Germany; <sup>§</sup>Department of Neurosurgery, University Medical Center Mannheim, Mannheim, Germany; <sup>||</sup>Department of Radiation Oncology, Klinikum Rechts der Isar, Technical University of Munich, Munich, Germany; <sup>¶</sup>Department of Radiation Oncology, A. C. Camargo Cancer Center, São Paulo, Brazil; <sup>#</sup>Department of Neurosurgery, University Hospital Bonn, Bonn, Germany; <sup>\*\*</sup>Department of Neurosurgery, West Virginia University, Morgantown, West Virginia; <sup>††</sup>Institute of Neuropathology, University Hospital Bonn, Bonn, Germany; <sup>‡‡</sup>Division of Clinical Neuro-Oncology, Department of Neurology, University Hospital Bonn, Bonn, Germany; <sup>§§</sup>Department of Radiation Oncology, University Medical Center Mannheim, Mannheim, Germany; <sup>||</sup>DKFZ-Hector Cancer Institute of the University Medical Center Mannheim, Mannheim, Germany; <sup>¶¶</sup>Mannheim Institute of Intelligent Systems in Medicine (MIISM), Medical Faculty Mannheim, University of Heidelberg, Mannheim, Germany; and <sup>##</sup>Department of Radiooncology, University Hospital Augsburg, Augsburg, Germany

Received Aug 11, 2023; Accepted for publication Jan 3, 2024

Corresponding author: Gustavo R. Sarria, MD; E-mail: [gustavo.sarria@ukbonn.de](mailto:gustavo.sarria@ukbonn.de)

Gustavo R. Sarria and Klaus-Henning Kahl made equal contributions to this study.

Disclosures: J.P.L. reports stocks and travel expenses from TME Pharma AG, travel expenses from Carl Zeiss Meditec AG, stocks and honoraria from Siemens Healthineers, and stocks from Bayer AG and BioNTech AG. S.B. reports travel expenses and honoraria from Carl Zeiss Meditec AG. C.D.D. reports travel expenses from Carl Zeiss Meditec AG. M.H. reports travel expenses from Carl Zeiss Meditec AG. H.V. reports travel expenses from Carl Zeiss Meditec AG. M.S. reports travel expenses from Carl Zeiss Meditec AG. S.E.C. reports travel expenses and honoraria from Carl Zeiss Meditec AG. L.C.S. reports travel expenses from Carl Zeiss Meditec AG. C.P.C. reports travel expenses and speaking honoraria from Carl Zeiss Meditec AG. F.A.G. reports research grants and travel expenses from Elekta AB and Varian Medical Systems, Inc; grants, stocks, travel expenses, and honoraria from TME Pharma AG; research grants, travel expenses, and honoraria from Carl Zeiss Meditec AG; travel expenses and honoraria from Bristol-Myers Squibb, Cureteq AG,

Guerbet SA, Roche Pharma AG, MSD Sharp & Dohme GmbH, and AstraZeneca GmbH; and nonfinancial support from Oncare GmbH and Opasca GmbH. G.R.S. reports personal fees and travel expenses from Carl Zeiss Meditec AG, personal fees from MedWave Clinical Trials, and travel expenses from Guerbet SA. K.-H.K. reports honoraria and travel expenses from Varian, Elekta AB, Carl Zeiss Meditec AG, AstraZeneca, Roche, Icotec AG, Bristol-Myers Squibb, MSD Sharp & Dohme, Merck, and Sanofi-Aventis and advisory board membership for Bristol-Myers Squibb, MSD Sharp & Dohme, Merck, and Sanofi-Aventis.

**Data Sharing Statement:** The data presented in this study are available in the article. Further data sets generated and/or analyzed during the current study are available from the corresponding author on reasonable request.

**Acknowledgments—**We thank Katja Klever and Monika Brüggemann for their support in patient follow-up and the medical team of Helmut Forstbauer for aiding in data acquisition.

Supplementary material associated with this article can be found in the online version at [doi:10.1016/j.ijrobp.2024.01.009](https://doi.org/10.1016/j.ijrobp.2024.01.009).

**Purpose:** After surgical resection of brain metastases (BMs), intraoperative radiation therapy (IORT) provides a promising alternative to adjuvant external beam radiation therapy by enabling superior organ-at-risk preservation, reduction of in-hospital times, and timely admission to subsequent systemic treatments, which increasingly comprise novel targeted immunotherapeutic approaches. We sought to assess the safety and efficacy of IORT in combination with immune checkpoint inhibitors (ICIs) and other targeted therapies (TTs).

**Methods and Materials:** In a multicentric approach incorporating individual patient data from 6 international IORT centers, all patients with BMs undergoing IORT were retrospectively assessed for combinatorial treatment with ICIs/TTs and evaluated for toxicity and cumulative rates, including wound dehiscence, radiation necrosis, leptomeningeal spread, local control, distant brain progression (DBP), and estimated overall survival.

**Results:** In total, 103 lesions with a median diameter of 34 mm receiving IORT combined with immunomodulatory systemic treatment or other TTs were included. The median follow-up was 13.2 (range, 1.2-102.4) months, and the median IORT dose was 25 (range, 18-30) Gy prescribed to the applicator surface. There was 1 grade 3 adverse event related to IORT recorded (2.2%). A 4.9% cumulative radiation necrosis rate was observed. The 1-year local control rate was 98.0%, and the 1-year DBP-free survival rate was 60.0%. Median time to DBP was 5.5 (range, 1.0-18.5) months in the subgroup of patients experiencing DBP, and the cumulative leptomeningeal spread rate was 4.9%. The median estimated overall survival was 26 (range, 1.2 to not reached) months with a 1-year survival rate of 74.0%. Early initiation of immunotherapy/TTs was associated with a nonsignificant trend toward improved DBP rate and overall survival.

**Conclusions:** The combination of ICIs/TTs with IORT for resected BMs does not seem to increase toxicity and yields encouraging local control outcomes in the difficult-to-treat subgroup of larger BMs. Time gaps between surgery and systemic treatment could be shortened or avoided. The definitive role of IORT in local control after BM resection will be defined in a prospective trial. © 2024 The Authors. Published by Elsevier Inc. This is an open access article under the CC BY license (<http://creativecommons.org/licenses/by/4.0/>)

## Introduction

The rise of novel immunotherapeutic agents has redrawn the treatment patterns for many tumor entities in recent years.<sup>1,2</sup> As a consequence of improved local control and prolonged survival, the diagnostic incidence of brain metastases (BMs) has increased significantly,<sup>3,4</sup> with nearly every second patient developing BMs over the course of the disease.<sup>5,6</sup> This is also attributed to the fact that many novel immunotherapeutic drugs cannot penetrate the blood-brain barrier (BBB) sufficiently to induce stable tumor control within the brain.<sup>7,8</sup> Although overall survival (OS) is largely dictated by extracranial disease progression,<sup>9</sup> BMs usually require medical intervention to prevent or stabilize neurologic deterioration and impairment of quality of life.<sup>10,11</sup> Local treatment options include surgery, radiosurgery, fractionated stereotactic radiation therapy (RT), and surgery followed by adjuvant RT of the resection cavity. Surgery and adjuvant RT are usually indicated for larger BMs to improve local control rates, as smaller-volume BMs do not need surgery.<sup>12-14</sup> Although the most common form of RT application is stereotactic external beam RT (EBRT) with 1 to 7 fractions,<sup>12-15</sup> intraoperative RT (IORT) provides an excellent alternative, yielding equal clinical outcomes<sup>16-19</sup> with superior organ-at-risk (OAR) preservation<sup>20</sup> and a favorable toxicity profile.<sup>21,22</sup> However, data are very limited regarding potential desirable and undesirable effects<sup>23,24</sup> of concomitant or sequential treatment with increasingly available immunostimulating systemic therapy.<sup>25</sup> We thus sought to assess the safety and efficacy of combination treatment with IORT to BMs and immunotherapy (IT) in this multicentric retrospective series.

## Methods and Materials

### Patients

In a multicentric approach, patient databases of 4 European, 1 North American, and 1 South American university hospitals were retrospectively screened for patients with BMs receiving IORT with concomitant or sequential IT or targeted therapy (TT) between 2014 and 2023. IT was defined as authority-approved administration of an ICI (ie, anti-PD-L1, anti-PD-1, and anti-CTLA4). TT was defined as authority-approved administration of a drug using a tumor-specific nonimmunogenic or immunogenic target other than immune checkpoint blockade (ie, BRAF/MEK inhibition, [multi-]tyrosine kinase inhibition, or antibodies against essential tumor signaling pathways). For inclusion, at least 1 available imaging follow-up (FU) and information on received systemic treatment were mandatory. All patients underwent surgical resection and IORT following interdisciplinary evaluation in a neuro-oncological tumor board. BMs were pathologically confirmed in all cases. The criteria for surgical resection were presence or severe risk of acute neurologic impairment, clinically significant mass effects as abnormal intracranial pressure or hemispheric shift, and histopathologic confirmation of diagnosis in case of cancer of unknown primary. Only the clinically relevant lesion receiving IORT was considered for surgical removal in case of multiple BMs. Requirements for IORT were gross total resection, intraoperative confirmation of BM on frozen tumor sections, and fulfillment of dose constraints. The data collected from eligible patients included sociodemographic characteristics, functional status with Karnofsky performance score, tumor location, histology, baseline

and FU radiologic features of the lesion, and systemic therapy status. Diagnostic-Specific Graded Prognostic Assessment (DS-GPA)<sup>26</sup> scores were calculated by standard procedures.

## IORT

Three-dimensional image guidance for both surgery and IORT was provided by preoperative contrast-enhanced T1-weighted magnetic resonance imaging (MRI). The optic nerve, optic chiasm, and brain stem were identified preoperatively and intraoperatively as OARs for IORT, and delivered doses were defined based on dose-depth template profiles corresponding to each applicator diameter. Following macroscopic complete resection of the lesion, a frozen section was assessed intraoperatively by a board-certified neuropathologist, confirming the presence of malignant cells with an extracranial solid tumor origin. Neurosurgical MRI navigation was used to intraoperatively assess the minimum distance of the resection cavity to OARs and cavity extends, followed by selection of the optimal fitting for spherical applicators ranging from 1.5 to 5.0 cm in diameter. The selected applicator was placed in the resection cavity without applying pressure to the adjacent healthy brain tissue but with the aim of ubiquitous direct tissue contact avoiding air entrapment for optimal dose distribution. The IORT was only performed when a safe and orderly execution was ensured. The INTRABEAM 600 (Carl Zeiss Meditec AG) was used to deliver IORT by application of nominal 50-kV photons at a standard dose of 20 to 30 Gy prescribed to the applicator surface. The dose profile in depth was obtained before each procedure according to preperformed Monte Carlo calculations with radiance (GMV). Decreasing the prescribed dose down to 16 Gy was acceptable in case of OAR doses exceeding the constraints of 8 Gy to the optical system or the brain stem following QUANTEC (Quantitative Analyses of Normal Tissue Effects in the Clinic) recommendations<sup>27</sup> with consideration of the specific (1.3–1.5 times higher) relative biologic effectiveness of low-energy photons. In individual cases, anatomic positioning of the applicator required consideration of a further, not regularly assessed, OAR (eg, cochlea or thalamus) with equal consideration of the QUANTEC recommendations. The irradiation time ranged from 7 to 49 minutes depending on the applicator size and the prescribed dose. Following removal of the applicator, the surgery was continued as per standard procedures with wound sealing.

## Follow-up

All patients had regular FU visits, including physical examination and MRI, as per guideline recommendations. Adverse events (AEs) were assessed and graded by clinicians according to the National Cancer Institute Common Terminology Criteria for Adverse Events, version 5.0. Acute toxicities were considered AEs occurring within the first 8 weeks of FU, whereas late toxicities were defined as all AEs recorded

at a later time point. MRI assessments were performed according to the RANO criteria<sup>28</sup> by board-certified radiologists. In case of uncertain clinical/radiographic response, the interdisciplinary neuro-oncological tumor board was consulted for shared decision-making. The following conditions qualified for diagnosis of radiation necrosis (RN): (1) after initial suspected progressive disease (PD), a minimum of 2 FU MRIs showed no sign of ongoing PD; (2) advanced MRI incorporating dynamic susceptibility contrast perfusion imaging or diffusion-weighted imaging was concordantly suggestive of RN; (3) positron emission tomography imaging, such as <sup>18</sup>F-fluoroethyl-tyrosine positron emission tomography, with findings consistent with RN; and (4) RN was confirmed histopathologically following resection.

## Study endpoints

The primary endpoints were toxicity, namely cumulative RN rates, and 1-year local control rate (LCR). The secondary endpoints were cumulative distant brain progression (DBP) rates, leptomeningeal spread (LMS) rates, 1-year OS rates, and estimated OS. For toxicity assessment, simultaneous IORT and IT/TT was defined as an initiation of treatment within the first 2 months after date of surgery. Local control was defined as the absence of MRI radiographic PD, as per RANO-BM criteria,<sup>28</sup> within 1 cm surrounding the previously irradiated BM resection cavity and absence of clinical deterioration attributable to the treated lesion. Local control was calculated from the day of surgery until the local PD date. Patients lost to FU or deceased before radiographic progression were censored at the last FU time point. DBP was defined as an MRI radiographic emergence/progression of intracranial lesions, as per RANO-BM criteria, in at least 1-cm distance to the resection cavity receiving IORT or clinical deterioration not attributed to the IORT but a distant brain lesion. DBP rates were calculated from the day of surgery to the PD date. Patients lost to FU or deceased before the event were censored at the last FU time point. LMS was defined as either MRI radiographic suspicion or cytologic confirmation of pachymeningeal or leptomeningeal tumor cell spread. OS was defined as the time interval between the date of surgery and the date of either the last FU (censored) or death.

## Ethics

This study was conducted in accordance with the principles of the Declaration of Helsinki and was approved by the Ethics Committee of the University Hospital Bonn (approval number: 057/22).

## Statistics

The software package used for the data analyses was GraphPad Prism (version 9, GraphPad Software). Figures and

graphs were created using GraphPad Prism and Adobe Illustrator 2023 (Adobe, Inc). Descriptive statistics incorporated the calculation of percentages and median values with minimum to maximum range. For survival analysis, the Kaplan-Meier method was used and curves with 95% confidence intervals were generated. Hazard ratios and their 95% confidence intervals were calculated using the Mantel-Haenszel method. The Fisher exact test was used to analyze categorical variables. The Mann-Whitney test was used to compare continuous variables, as the data were not normally distributed. Statistical significance was defined as  $P < .05$ . The particular statistical methods applied are specified in the corresponding figures.

## Results

### Patient and tumor characteristics

A total sample size (n) of 114 consecutive patients with BMs receiving IORT to the resection cavity combined with immune checkpoint inhibitors (ICIs) or other TTs were screened. Of these, sufficient FU information (at least 1 imaging FU and systemic therapy information) was available for 99 patients with 105 treated lesions. Two cases were removed from the outcome analyses because the IORT lesion received additional immediate stereotactic body RT, leaving a total of 103 lesions analyzed. The median patient age was 63 years (range, 35-85; n = 99), and the median Karnofsky performance score was 80 (range, 40-100). The median DS-GPA score was 2 (range, 0-4; n = 99). The most frequent BM localization was the frontal lobe (35.0%), whereas most histopathology results corresponded to lung cancer (54.4%). With a range of 1 to 16 intracranial lesions, 48 cases (46.6%) suffered from multiple BMs at the time of surgery. Further details on patient characteristics are provided in [Table 1](#).

### Treatment

The median FU was 13.2 (range, 1.2-102.4; n = 99) months. The brain stem and optic tracts (optic nerve and chiasma) were regularly assessed as OARs, and no dose constraints were exceeded. All patients completed treatment. The median IORT prescription dose was 25 Gy (range, 16-30; n = 103) to the surface, which corresponds to a dose delivery of approximately 60% in 3 mm, 45% in 5 mm, and 22% in 10 mm tissue depth, slightly varying depending on applicator diameter. The median applicator size was 2 cm (range, 1.5-4.0; n = 103). Whereas 90 patients (87.4%) received IORT plus ICIs, another 25 patients (24.3%) received other TTs. Of note, some patients received both ICI and TT in parallel or combinations of either substance group. The median time to ICI initiation after IORT was 1.1 (range, -22.3 to 34; n = 90) months. TT was initiated after a median time of 1.2 months (range, -38.9 to 22.9; n = 25).

**Table 1 Patient characteristics for the evaluated BMs (n = 103)**

Variable	No. (%)	Median (range)
Gender		
Male	56 (54.4)	
Female	47 (45.6)	
Age (y)		63 (35-85)
Tumor entity		
NSCLC	53 (51.5)	
Melanoma	25 (24.3)	
RCC	13 (12.6)	
Breast	4 (3.9)	
SCLC	3 (2.9)	
Others	5 (4.9)	
Localization		
Frontal lobe	36 (35.0)	
Parietal lobe	28 (27.2)	
Occipital lobe	18 (17.5)	
Temporal lobe	13 (12.6)	
Cerebellum	8 (7.8)	
Maximum presurgical diameter (mm)		34 (8-70)
Presurgical tumor volume (cm <sup>3</sup> )		22.9 (1.2-701.7)
Multiple BMs	48 (46.6)	
Number of BMs		1 (1-16)
RT to other BMs	50 (48.5)	
Relevant overlap (≥10% isodose)	14 (13.6)	
Extracranial metastases	66 (64.1)	
KPS		80 (40-100)
DS-GPA		2 (0-4)

*Abbreviations:* BM = brain metastasis; DS-GPA = Diagnostic-Specific Graded Prognostic Assessment; KPS = Karnofsky performance score; NSCLC = non-small cell lung cancer; RCC = renal cell carcinoma; RT = radiation therapy; SCLC = small cell lung cancer.

[Table 2](#) depicts further treatment characteristics and lists the specific administered substances.

### Toxicity

Under combinatory treatment, mild and anticipated toxicity was reported. A summary of the observed AEs is provided in [Table 3](#). No grade 4 or 5 events were deemed related to IORT. [Figure 1a](#) and [b](#) show the maximum toxicity observed for individual patients. A cumulative RN rate of 4.9% (n = 5) was observed with a median time to RN of 12.8 (range, 7.8-

**Table 2 Treatment characteristics (n = 103)**

Variable	No. (%)	Median (range)
IORT dose (Gy)		25 (16-30)
18	5 (4.9)	
20	40 (38.8)	
24	4 (3.9)	
25	3 (2.9)	
26	1 (1.0)	
30	50 (48.5)	
Applicator diameter (mm)		20 (15-40)
Time from first diagnosis to IORT (mo)		1 (0-297)
Immune checkpoint inhibitor	90 (87.4)*	
Pembrolizumab	36 (40.0)	
Ipilimumab + nivolumab	20 (22.2)	
Atezolizumab	16 (15.5)	
Nivolumab	13 (14.4)	
Durvalumab	4 (4.4)	
Ipilimumab	1 (1.1)	
Time from IORT to IT (mo)		1.1 (–22.3 to 34)
Number of IT cycles		6 (1-93)
TT drug	25 (24.3)*	
BRAF/MEK inhibitor	6 (24.0)	
TKI	5 (20.0)	
MKI	6 (24.0)	
VEGF targeting*	6 (24.0)	
Androgen deprivation	3 (12.0)	
Anti-HER2neu	3 (12.0)	
Anti-TNF $\alpha$	1 (4.0)	
Time from IORT to TT (mo)		1.2 (–38.9 to 22.9)
Duration of TT treatment (mo)		7 (2-68)
<i>Abbreviations:</i> IT = immunotherapy; IORT = intraoperative radiation therapy; MKI = multikinase inhibitor; TKI = tyrosine kinase inhibitor; TT = targeted therapy.		
* Some patients received both IT and TT in parallel or combinations of either substance group.		

18.9) months (Fig. 1c). Of these RN events, 4 were grade 1, and 1 was grade 3. The latter occurred in a patient with renal cell carcinoma receiving IORT with 30 Gy to a frontal 34-mm BM after 7.8 months. This patient had received systemic treatment with cabozantinib initiated 5 weeks after surgery for a total of 7 months before it was terminated due to an unfavorable overall toxicity profile. The RN was treated successfully with bevacizumab after previous failure of dexamethasone treatment. No wound dehiscences of any grade were noted. There were significantly more severe AEs ( $P = .049$ ; Fig. 1d) in total but also treatment-related AEs ( $P = .025$ ; Fig. 1e; RN and autoimmune infection) recorded for patients who commenced systemic treatment in parallel to resection and IORT, defined as initiation of treatment

within the first 2 months following surgery. The full list of acute and long-term AEs is provided in Table E1.

## Outcome

The overall 1-year and 2-year LCRs were 98.0% (Fig. 2a) and 93.7%, respectively. With an overall DBP rate of 36.9%, the median DBP-free rate was not reached, while the 1-year DBP-free survival rate was 60.0% (Fig. 2b). The median time to DBP was 5.5 (range, 1.0-18.5;  $n = 38$ ) months in the subgroup of patients experiencing distant intracranial progression. The cumulative LMS rate was 4.9% with a median time to LMS of 6.2 (range, 4.2-18.2) months (Fig. 2c). The

**Table 3** Summary of adverse events (n = 147)

	Acute events	Late events	All events
Grade	No. (%)	No. (%)	No. (%)
1	22 (44.9)	43 (43.9)	65 (44.2)
2	20 (40.8)	18 (18.4)	38 (25.9)
3	6 (12.2)	33 (33.7)	39 (26.5)
4	1 (2.0)*	2 (2.0)†	3 (2.0)
5	0 (0.0)	2 (2.0)‡	2 (1.4)
Any grade	49 (33.3)	98 (66.7)	147 (100.0)

\* Fulminant autoimmune hepatitis unrelated to intraoperative radiation therapy but likely related to pembrolizumab.  
† One patient experienced immune checkpoint inhibitor–related autoimmune vasculitis of grade 4 under pembrolizumab, and another patient experienced an unrelated cardiac infarction causing pulmonary vein congestion and ultimately an atypical pneumonia.  
‡ An 81-year-old patient with lung cancer experienced reactivation of a pre-existing chronic lymphocytic leukemia, ultimately causing his demise following septicemia. Another patient died due to distant brain progression-related intracranial bleeding 4 months after intraoperative radiation therapy.

median OS after IORT was 26 months (range, 1.2 to not reached), and the 1-year OS rate was 74.0% (Fig. 2d). The initiation of IT/TT within 2 months following IORT was associated with a nonsignificant trend toward prolongation of both distant brain control and OS (Fig. 2e). There were no variables significantly associated with local recurrence or RN in uni- or multivariate analysis, whereas DS-GPA provided the best prognostic separation (hazard ratio, 0.05;  $P = .173$ ) for local recurrence. However, median-based classification of the dose prescription ( $\leq 24$  Gy vs  $\geq 25$  Gy) showed a trend for increased RN risk ( $P = .158$ ; Fig. E1), but not local recurrence ( $P > 0.999$ ), DBP-free survival ( $P = .782$ ), or OS ( $P = .318$ ). Age ( $P = .022$ ) and DS-GPA ( $P = .049$ ) were significantly associated with OS in multivariate analysis.

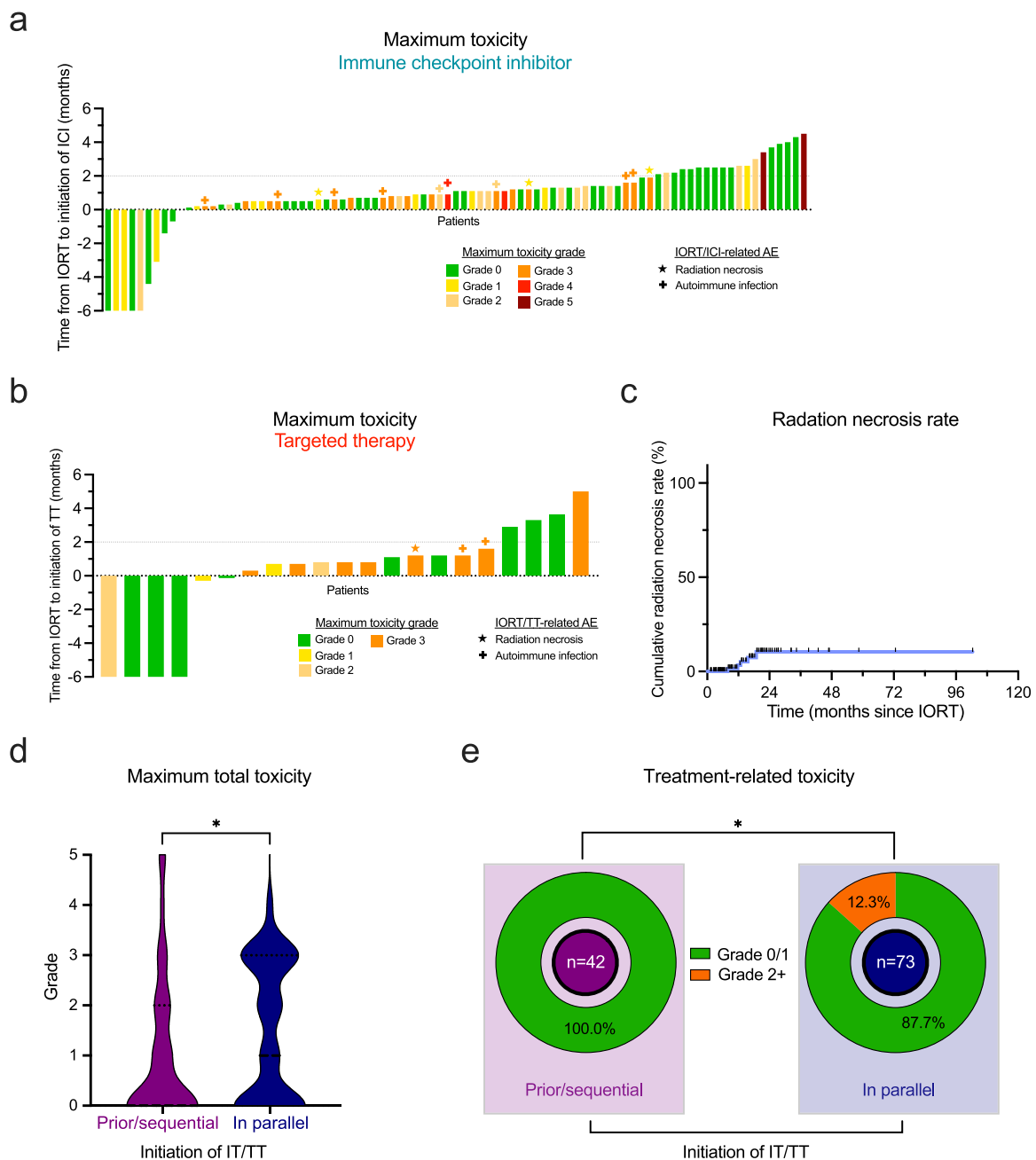
## Discussion

In contrast to the preceding era of uniform chemotherapy, ITs have recently reshaped the landscape of oncology dramatically toward precision-tailored treatments. This success is due to promising efficacy in a growing number of tumor entities and good patient tolerability with a relatively favorable toxicity profile, also in combination with other local or systemic therapies. Here, we provide evidence that IORT is an overall well-tolerated combination partner for ICI and other novel TTs.

In particular, in highly immunogenic entities, such as melanoma, there are several reports of synergistic systemic effects of combined focal RT and systemic IT, often referred to as the *abscopal effect*.<sup>29,30</sup> However, the brain was long considered a privileged organ where the underlying mechanisms do not apply due to the filtering properties of the

BBB, thus preventing sufficient penetration of the tumor tissue and limiting the bioavailability of drugs<sup>8</sup> in an a priori immune-cold, secluded microenvironment.<sup>31</sup> Nevertheless, there are numerous clinical case reports of abscopal systemic tumor responses following high-dose RT of BMs, particularly with concomitant IT.<sup>32,33</sup> Recent advances in research have shed more light on the characteristics of the immunologic tumor microenvironment of BMs, claiming a very distinct, yet nonnegligible, role of the immune system for brain compartments.<sup>34–36</sup> RT generates neoantigens,<sup>37</sup> activates nonredundant immune pathways in the tumor,<sup>38</sup> and increases permeability of the BBB, thus improving brain penetration of ITs/TTs.<sup>39</sup> These mechanisms make RT a specifically interesting combination partner for targeted approaches in entities and individual patients considered nonresponsive to treatment.<sup>40</sup>

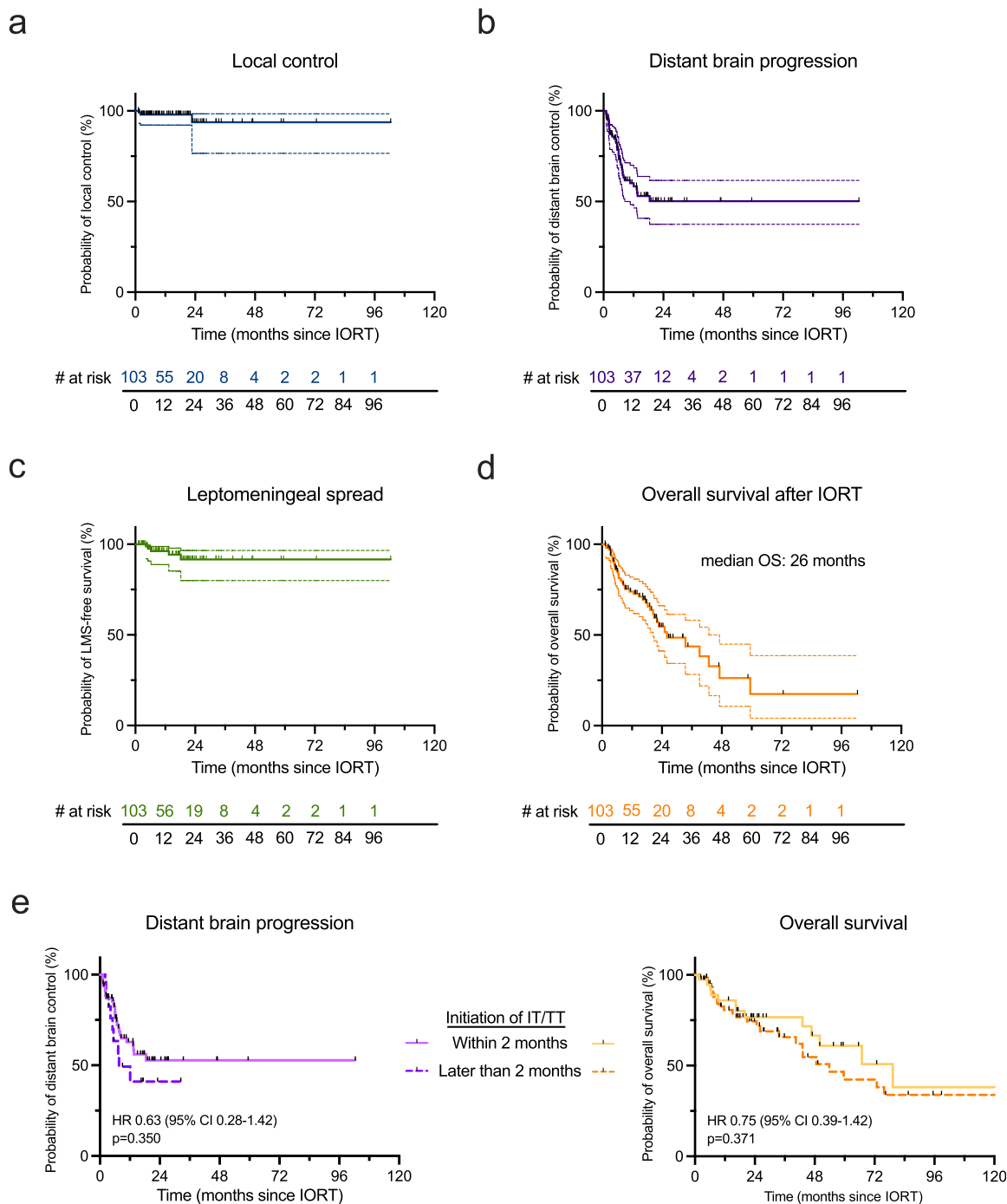
Independent of prognostic factors, BM resection necessitates additional RT to improve local tumor control. Nonetheless, depending on individual tumor features and clinical context, it remains controversial which RT sequencing and technique achieves the best long-term outcomes at the lowest toxicity levels. Our observed 1-year LCR of 97.1% is in line with previous reports on IORT<sup>16,19</sup> and furthermore strengthens the notion that this RT technique might be superior to both definitive and adjuvant EBRT regimens where LCRs of 85% to 90% can be expected at most.<sup>12,14,15,41–43</sup> Yet, prospective trials are required to confirm this hypothesis. A large pooled analysis with 179 patients assessed very recently outcomes for the combination of stereotactic body RT and IT,<sup>44</sup> reporting a LCR of 94.2% and a cumulative grade  $\geq 2$  RN rate of 6.9% after a median FU of 14.8 months. Notably, the median diameter of the investigated lesions was only 7 mm. With a median lesion diameter of 34 mm, we provide with IORT plus IT/TT a treatment rationale with particularly good outcome and tolerability for large lesions. Of note, the tumor lesions reported here are measured presurgically for obvious technical reasons, but adjuvant EBRT faces the dilemma of about 30% target volume increase.<sup>45</sup> This additionally strengthens the data provided here for these already presurgically large lesions with a median volume of 22.9 cm<sup>3</sup>. Furthermore, larger lesion size was not associated with inferior outcome in this collective. Besides good local tumor control, we also demonstrated convincing intracranial control with a 1-year DBP-free survival of 60.0% and a cumulative LMS rate of only 4.8%. Although the exact underlying mechanisms remain unknown and require further scientific attention, a positive effect of the instant dose application thus preventing intracranial spread or LMS of tumor cells from around the resection cavity appears reasonable. Besides this timely eradication of remaining tumor cells, IORT may synergistically prevent the re-establishment of a protumorigenic tumor microenvironment. IT and TT may benefit from the high-dose local RT effects facilitating antigen presentation and subsequent immune-stimulatory properties, thereby enabling more effective killing of distantly circulating tumor cells.<sup>24</sup> Proteomic profiles of wound fluids from patients



**Fig. 1.** Toxicity profile of IORT with immune checkpoint inhibition or other targeted therapies. (a, b) Waterfall plot illustrating time from IORT to initiation of ICI therapy (a) and TT (b) for each individual patient with treatment initiation between 6 months before and after IORT. Color labeling represents the maximum overall toxicity observed as per CTCAE grading (independent of the relation to treatment), and icons symbolize occurrence of therapy-associated AEs (IORT/ IT/TT-related AEs). (c) Cumulative radiation necrosis rate (%) over time in months since IORT. (d) Violin plots demonstrating the distribution of the maximum reported toxicity as per CTCAE grading for patients receiving IT/TT before or after (later than 2 months following surgery) IORT compared with treatment initiation in parallel with IORT (within 2 months following surgery). Dashed lines indicate the median;  $*P < .05$ , Mann-Whitney test. (e) Donut chart depicting maximum grade IORT/IT/TT-related toxicity (grade  $\leq 1$  vs grade  $\geq 2$ ) depending on time point of IT/TT initiation as defined in (d).  $*P > .05$ , Fisher exact test. *Abbreviations:* AE = adverse event; CTCAE = Common Terminology Criteria for Adverse Events; ICI = immune checkpoint inhibitor; IORT = intraoperative radiation therapy; IT = immunotherapy; TT = targeted therapy.

with breast cancer exhibited an abrogation of pathways promoting migration and invasiveness following IORT, which may explain the LCRs and DBP-free survival observed in

particular.<sup>46</sup> Furthermore, the kV energy of photon-IORT delivers 1.3 to 1.5 times higher relative biological effectiveness,<sup>47</sup> possibly overcoming typical limitations of common



**Fig. 2.** Outcome parameters of IORT with immune checkpoint inhibition and other targeted therapies. (a-d) Kaplan-Meier plots depicting percent local control rate (a), distant brain progression-free survival (b), leptomeningeal spread-free survival (c), and overall survival (d) over time in months since IORT. Dashed lines indicate 95% CIs. (e, f) Kaplan-Meier plots for distant brain progression-free survival (e) and overall survival (f) dependent on time point of IT/TT initiation (within vs later than 2 months after IORT). HRs with CIs and *P* values are indicated in the lower left corner and were calculated for initiation of IT/TT within 2 months versus later than 2 months. Data were analyzed by log-rank test. *Abbreviations:* HR = hazard ratio; IT = immunotherapy; LMS = leptomeningeal spread; OS = overall survival; TT = targeted therapy.

RT dosing like tumor hypoxia, repair, and reduced radiosensitivity of surviving tumor cells.<sup>48</sup> Nevertheless, the sharp fall-off dose profile of IORT<sup>20</sup> might prevent a farther in-depth tumoricidal effect, which is the principle of EBRT

delivery modalities.<sup>15</sup> Yet, the healthy brain-sparing properties of IORT prevent both neurologic and cognitive impairment of patients and allow for targeted reirradiation in case of distant recurrence.

The “one-stop-shop” characteristic of IORT enables timely admission to subsequent systemic treatments while reducing in-hospital times<sup>49</sup> and might furthermore allow for earlier reduction of often necessary systemic corticosteroids than EBRT, which is a known risk factor for TT efficacy predominantly in the early initiation phase.<sup>50</sup> Although the OS reported in this series needs to be interpreted cautiously due to its retrospective nature and potential selection bias, we additionally provide first evidence of encouraging survival outcomes following combinatorial treatment, at least noninferior to previous reports on IORT<sup>18</sup> but also a matched retrospective comparison of IORT and EBRT cases.<sup>19</sup> As mentioned, this is hypothesis generating and should be evaluated within a prospective clinical trial.

Overall, our data indicate good tolerability and a favorable safety profile of this combinatorial approach. While predominantly confirming a lack of sufficient data for most drugs, a systematic meta-analysis previously reported generally acceptable toxicity of cranial stereotactic EBRT with IT.<sup>51</sup> Yet, TTs and, in particular, BRAF inhibitors were associated with a high risk of severe toxicity,<sup>51</sup> which we cannot confirm for our IORT cohort. The toxicity reported here is rather mild and in line with previous reports on IORT, which did not specifically address IT/TT cases.<sup>21,22</sup> Of note, only a minority of IORT patients of previous series received concomitant systemic therapy at all. Patel et al observed a nonsignificant trend toward higher RN incidence for RT and ipilimumab versus RT only.<sup>52</sup> Regardless of this, the reported RN rate of 30% significantly exceeds the cumulative RN rate of 5.7% presented here, despite the numerous patients in this collective receiving duplet immune checkpoint blockade, which is associated with increased toxicity,<sup>2</sup> let alone a less favorable toxicity profile in combination with stereotactic radiotherapy (SRT).<sup>53</sup> Similar to previous retrospective single-center reports,<sup>16-19</sup> IORT patients seem to have a very low RN risk, which is not altered by concomitant IT/TT.

Timing of IT matters, but the optimal sequence of and time intervals between RT and IT remain controversial. Patient- and tumor-centered factors cannot be excluded to additionally influence this question. The PACIFIC trial showed strong evidence for sequential durvalumab treatment in locally advanced lung cancer with a time gap of at least 1 day but up to 6 weeks.<sup>1</sup> In the RTOG 3505 trial, IT with nivolumab was initiated 4 to 12 weeks after RT.<sup>54</sup> However, a large retrospective analysis noted improved clinical outcome when ICIs were started at least 1 month before RT.<sup>55</sup> This divergence prompted us to assess the IORT + IT effects in a wide time range of treatment initiation and to investigate possible timing effects. Within the low-toxicity collective reported here, we notably observed increased toxicity for the subgroup of patients commencing their systemic treatment not before but in the first 2 months following resection and IORT. Additionally, we noted a trend toward improved clinical outcome in both of these groups compared with even later initiation of IT. While requiring confirmation in prospective data, this would

contradict the common concept of preventing increased perioperative risks by decidedly long postsurgery treatment gaps but suggest a benefit regarding both outcome and tolerability for even earlier, preinterventional initiation of the systemic treatment.

Wound dehiscence is a common complication following BM resection,<sup>56,57</sup> with reported increased incidence for synchronous IT in head and neck cancer.<sup>58</sup> In this series, we observed not a single case of wound dehiscence, rendering IORT safe for patients with BMs receiving IT/TT. Notably, there is a well-known risk for wound infections with concomitant bevacizumab,<sup>59</sup> which was underrepresented in our collective with just 2 patients receiving this VEGF pathway TT. Our data are thus in accordance with previous reports that claim fewer toxicities for cranial RT with bevacizumab than for extracranial RT.<sup>51</sup> It is worth highlighting that 2 patients were a priori removed from the analyses due to receiving an additional sequential SRT boost after IORT. One of these patients with renal cell carcinoma receiving the VEGF-targeting multikinase inhibitor axitinib and avolumab later experienced both a wound dehiscence requiring surgical intervention and grade 3 RN. Our observations raise suspicion over the safety of this treatment combination and suggest that RT prescription requires reconsideration, as IORT with a sequential SRT boost was previously reported to be related to higher toxicity.<sup>18</sup> Although IORT to BMs without sequential SRT boosting appears safe independent of the dose prescription, the results of the multivariate analyses suggest to limit the dose to 25 Gy to the surface. This limits the IORT duration and thus the window of risk for anesthesia side effects but may also be protective for RN while noninferior regarding clinical outcome. Again, this will have to be confirmed in larger prospective trials.

Our study has several limitations. The retrospective nature of the assessment may cause an incomplete portrait of toxicity compared with controlled prospective clinical trials as well as patient selection bias. This is particularly important because the multicenter aspect additionally attributes to heterogeneity in this regard. Notably, most of our patients presented with lung primary histology. Other histologies, such as breast cancer, were underrepresented. Furthermore, the IORT dose prescription and FU protocols of the contributing centers were not derived from a single trial and not homogenized, which may impact the generalizability of the findings. Given the current small number of IORT patients in this setting, randomized prospective data are required. Our efforts thus mark a first step toward a multicentric, prospective study of IORT cases in centers around the world to ease the interpretation of its therapeutic value. This is the largest investigation on an IORT patient cohort to date, incorporating patient data from over 100 BM treatments in 6 international tertiary referral centers, and it is the first assessment of IORT as a potential combination partner for IT and TT approaches, paving the way to a more patient-centered, fast, safe and individual care for patients with BMs.

## Conclusion

The combination of IT/TT with IORT for resected BMs does not seem to increase toxicity, while yielding encouraging local control and LMS rates, particularly for large BMs. Times between surgery and systemic treatment should be shortened with this approach, as timely admission to systemic therapy was associated with a trend toward improved clinical outcome. A prospective clinical trial will elucidate the actual role of IORT in this setting.

## References

- Antonia SJ, Villegas A, Daniel D, et al. Overall survival with durvalumab after chemoradiotherapy in stage III NSCLC. *N Engl J Med* 2018;379:2342-2350.
- Larkin J, Chiarion-Sileni V, Gonzalez R, et al. Combined nivolumab and ipilimumab or monotherapy in untreated melanoma. *N Engl J Med* 2015;373:23-34.
- Davis FG, Dolecek TA, McCarthy BJ, et al. Toward determining the lifetime occurrence of metastatic brain tumors estimated from 2007 United States cancer incidence data. *Neuro Oncol* 2012;14:1171-1177.
- Lamba N, Wen PY, Aizer AA. Epidemiology of brain metastases and leptomeningeal disease. *Neuro Oncol* 2021;23:1447-1456.
- Cagney DN, Martin AM, Catalano PJ, et al. Incidence and prognosis of patients with brain metastases at diagnosis of systemic malignancy: A population-based study. *Neuro Oncol* 2017;19:1511-1521.
- Chamberlain MC, Baik CS, Gadi VK, et al. Systemic therapy of brain metastases: Non-small cell lung cancer, breast cancer, and melanoma. *Neuro Oncol* 2017;19:i1-i24.
- Ishiyama H, Teh BS, Ren H, et al. Spontaneous regression of thoracic metastases while progression of brain metastases after stereotactic radiosurgery and stereotactic body radiotherapy for metastatic renal cell carcinoma: Abscopal effect prevented by the blood-brain barrier? *Clin Genitourin Cancer* 2012;10:196-198.
- Di Giacomo AM, Valente M, Cerase A, et al. Immunotherapy of brain metastases: Breaking a “dogma. *J Exp Clin Cancer Res* 2019;38:419.
- Yamamoto M, Sato Y, Serizawa T, et al. Subclassification of recursive partitioning analysis class II patients with brain metastases treated radiosurgically. *Int J Radiat Oncol Biol Phys* 2012;83:1399-1405.
- Schödel P, Schebesch K-M, Brawanski A, et al. Surgical resection of brain metastases—impact on neurological outcome. *Int J Mol Sci* 2013;14:8708-8718.
- Verhaak E, Gehring K, Hanssens PEJ, et al. Health-related quality of life of patients with brain metastases selected for stereotactic radiosurgery. *J Neurooncol* 2019;143:537-546.
- Mahajan A, Ahmed S, McAleer MF, et al. Post-operative stereotactic radiosurgery versus observation for completely resected brain metastases: A single-centre, randomised, controlled, phase 3 trial. *Lancet Oncol* 2017;18:1040-1048.
- Lehrer EJ, Peterson JL, Zaorsky NG, et al. Single versus multifraction stereotactic radiosurgery for large brain metastases: An international meta-analysis of 24 trials. *Int J Radiat Oncol Biol Phys* 2019;103:618-630.
- Eitz KA, Lo SS, Soliman H, et al. Multi-institutional analysis of prognostic factors and outcomes after hypofractionated stereotactic radiotherapy to the resection cavity in patients with brain metastases. *JAMA Oncol* 2020;6:1901-1909.
- Brown PD, Ballman KV, Cerhan JH, et al. Postoperative stereotactic radiosurgery compared with whole brain radiotherapy for resected metastatic brain disease (NCCTG N107C/CEC-3): A multicentre, randomised, controlled, phase 3 trial. *Lancet Oncol* 2017;18:1049-1060.
- Cifarelli CP, Brehmer S, Vargo JA, et al. Intraoperative radiotherapy (IORT) for surgically resected brain metastases: Outcome analysis of an international cooperative study. *J Neurooncol* 2019;145:391-397.
- Kahl K-H, Balagiannis N, Höck M, et al. Intraoperative radiotherapy with low-energy x-rays after neurosurgical resection of brain metastases—an Augsburg University Medical Center experience. *Strahlenther Onkol* 2021;197:1124-1130.
- Diehl CD, Pigorsch SU, Gempt J, et al. Low-Energy X-Ray Intraoperative Radiation Therapy (Lex-IORT) for resected brain metastases: A single-institution experience. *Cancers* 2022;15:14. (Basel).
- Layer JP, Hamed M, Potthoff A-L, et al. Outcome assessment of intraoperative radiotherapy for brain metastases: Results of a prospective observational study with comparative matched-pair analysis. *J Neurooncol* 2023;164:107-116.
- Sarria GR, Smalec Z, Muedder T, et al. Dosimetric comparison of upfront boosting with stereotactic radiosurgery versus intraoperative radiotherapy for glioblastoma. *Front Oncol* 2021;11 759873.
- Hamed M, Potthoff A-L, Layer JP, et al. Benchmarking safety indicators of surgical treatment of brain metastases combined with intraoperative radiotherapy: Results of prospective observational study with comparative matched-pair analysis. *Cancers* 2022;14:1515.
- Krauss P, Steininger K, Motov S, et al. Resection of supratentorial brain metastases with intraoperative radiotherapy. Is it safe? Analysis and experiences of a single center cohort. *Front Surg* 2022;9 1071804.
- Demaria S, Bhardwaj N, McBride WH, et al. Combining radiotherapy and immunotherapy: A revived partnership. *Int J Radiat Oncol Biol Phys* 2005;63:655-666.
- Weichselbaum RR, Liang H, Deng L, et al. Radiotherapy and immunotherapy: A beneficial liaison? *Nat Rev Clin Oncol* 2017;14:365-379.
- Haslam A, Prasad V. Estimation of the percentage of US patients with cancer who are eligible for and respond to checkpoint inhibitor immunotherapy drugs. *JAMA Netw Open* 2019;2 e192535.
- Sperduto PW, Kased N, Roberge D, et al. Summary report on the graded prognostic assessment: An accurate and facile diagnosis-specific tool to estimate survival for patients with brain metastases. *J Clin Oncol* 2012;30:419-425.
- Marks LB, Yorke ED, Jackson A, et al. Use of normal tissue complication probability models in the clinic. *Int J Radiat Oncol Biol Phys* 2010;76:S10-S19.
- Lin NU, Lee EQ, Aoyama H, et al. Response assessment criteria for brain metastases: Proposal from the RANO group. *Lancet Oncol* 2015;16:e270-e278.
- Grimaldi AM, Simeone E, Giannarelli D, et al. Abscopal effects of radiotherapy on advanced melanoma patients who progressed after ipilimumab immunotherapy. *Oncoimmunology* 2014;3:e28780.
- Koller KM, Mackley HB, Liu J, et al. Improved survival and complete response rates in patients with advanced melanoma treated with concurrent ipilimumab and radiotherapy versus ipilimumab alone. *Cancer Biol Ther* 2017;18:36-42.
- Engelhardt B, Vajkoczy P, Weller RO. The movers and shapers in immune privilege of the CNS. *Nat Immunol* 2017;18:123-131.
- Lin X, Lu T, Xie Z, et al. Extracranial abscopal effect induced by combining immunotherapy with brain radiotherapy in a patient with lung adenocarcinoma: A case report and literature review. *Thorac Cancer* 2019;10:1272-1275.
- Suwinski R. Combination of immunotherapy and radiotherapy in the treatment of brain metastases from non-small cell lung cancer. *J Thorac Dis* 2021;13:3315-3322.
- Louveau A, Smirnov I, Keyes TJ, et al. Structural and functional features of central nervous system lymphatic vessels. *Nature* 2015; 523:337-341.
- Quail DF, Joyce JA. The microenvironmental landscape of brain tumors. *Cancer Cell* 2017;31:326-341.
- Strickland MR, Alvarez-Breckenridge C, Gainor JF, et al. Tumor immune microenvironment of brain metastases: Toward unlocking antitumor immunity. *Cancer Discov* 2022;12:1199-1216.
- Lhuillier C, Rudqvist N-P, Yamazaki T, et al. Radiotherapy-exposed CD8<sup>+</sup> and CD4<sup>+</sup> neoantigens enhance tumor control. *J Clin Invest* 2021;131 e138740.

38. Twyman-Saint Victor C, Rech AJ, Maity A, et al. Radiation and dual checkpoint blockade activate non-redundant immune mechanisms in cancer. *Nature* 2015;520:373-377.
39. Sprowls SA, Arsiwala TA, Bumgarner JR, et al. Improving CNS delivery to brain metastases by blood-tumor barrier disruption. *Trends Cancer* 2019;5:495-505.
40. Lussier DM, Alspach E, Ward JP, et al. Radiation-induced neoantigens broaden the immunotherapeutic window of cancers with low mutational loads. *Proc Natl Acad Sci U S A* 2021;118 e2102611118.
41. Minniti G, Scaringi C, Paolini S, et al. Single-fraction versus multifraction ( $3 \times 9$  Gy) stereotactic radiosurgery for large (>2 cm) brain metastases: A comparative analysis of local control and risk of radiation-induced brain necrosis. *Int J Radiat Oncol Biol Phys* 2016;95:1142-1148.
42. Lehrer EJ, Ahluwalia MS, Gurewitz J, et al. Imaging-defined necrosis after treatment with single-fraction stereotactic radiosurgery and immune checkpoint inhibitors and its potential association with improved outcomes in patients with brain metastases: An international multicenter study of 697 patients. *J Neurosurg* 2022;138:1178-1187.
43. Layer JP, Layer K, Sarria GR, et al. Five-fraction stereotactic radiotherapy for brain metastases - a retrospective analysis. *Curr Oncol* 2023;30:1300-1313.
44. Hall J, Lui K, Tan X, et al. Factors associated with radiation necrosis and intracranial control in patients treated with immune checkpoint inhibitors and stereotactic radiotherapy. *Radiother Oncol* 2023;189 109920.
45. Jarvis LA, Simmons NE, Bellerive M, et al. Tumor bed dynamics after surgical resection of brain metastases: Implications for postoperative radiosurgery. *Int J Radiat Oncol Biol Phys* 2012;84:943-948.
46. Belletti B, Vaidya JS, D'Andrea S, et al. Targeted intraoperative radiotherapy impairs the stimulation of breast cancer cell proliferation and invasion caused by surgical wounding. *Clin Cancer Res* 2008;14:1325-1332.
47. Liu Q, Schneider F, Ma L, et al. Relative biologic effectiveness (RBE) of 50 kV x-rays measured in a phantom for intraoperative tumor-bed irradiation. *Int J Radiat Oncol Biol Phys* 2013;85:1127-1133.
48. Herskind C, Ma L, Liu Q, et al. Biology of high single doses of IORT: RBE, 5 R's, and other biological aspects. *Radiat Oncol* 2017;12:24.
49. Dejonckheere CS, Layer JP, Hamed M, et al. Intraoperative or postoperative stereotactic radiotherapy for brain metastases: Time to systemic treatment onset and other patient-relevant outcomes. *J Neurooncol* 2023;164:683-691.
50. Maslov DV, Tawagi K, Kc M, et al. Timing of steroid initiation and response rates to immune checkpoint inhibitors in metastatic cancer. *J Immunother Cancer* 2021;9 e002261.
51. Kroeze SGC, Fritz C, Hoyer M, et al. Toxicity of concurrent stereotactic radiotherapy and targeted therapy or immunotherapy: A systematic review. *Cancer Treat Rev* 2017;53:25-37.
52. Patel KR, Shoukat S, Oliver DE, et al. Ipilimumab and stereotactic radiosurgery versus stereotactic radiosurgery alone for newly diagnosed melanoma brain metastases. *Am J Clin Oncol* 2017;40:444-450.
53. Bodensohn R, Werner S, Reis J, et al. Stereotactic radiosurgery and combined immune checkpoint therapy with ipilimumab and nivolumab in patients with melanoma brain metastases: A retrospective monocentric toxicity analysis. *Clin Transl Radiat Oncol* 2023;39 100573.
54. Gerber DE, Urbanic JJ, Langer C, et al. Treatment design and rationale for a randomized trial of cisplatin and etoposide plus thoracic radiotherapy followed by nivolumab or placebo for locally advanced non-small-cell lung cancer (RTOG 3505). *Clin Lung Cancer* 2017;18:333-339.
55. Samstein R, Rimner A, Barker CA, et al. Combined immune checkpoint blockade and radiation therapy: Timing and dose fractionation associated with greatest survival duration among over 750 treated patients. *Int J Radiat Oncol Biol Phys* 2017;99:S129-S130.
56. Barami K, Fernandes R. Incidence, risk factors and management of delayed wound dehiscence after craniotomy for tumor resection. *J Clin Neurosci* 2012;19:854-857.
57. Gupta S, Dawood H, Giantini Larsen A, et al. Surgical and peri-operative considerations for brain metastases. *Front Oncol* 2021;11 662943.
58. Mays AC, Yarlagadda B, Achim V, et al. Examining the relationship of immunotherapy and wound complications following flap reconstruction in patients with head and neck cancer. *Head Neck* 2021;43:1509-1520.
59. Sharma K, Marcus JR. Bevacizumab and wound-healing complications: Mechanisms of action, clinical evidence, and management recommendations for the plastic surgeon. *Ann Plast Surg* 2013;71:434-440.