



# A multi-center, clinical analysis of IDH-mutant gliomas, WHO Grade 4: implications for prognosis and clinical trial design

Ethan A. Wetzel<sup>1</sup> · Amin I. Nohman<sup>2,3</sup> · Annie L. Hsieh<sup>4</sup> · David Reuss<sup>5,6</sup> · Andreas W. Unterberg<sup>2,3</sup> · Ilker Y. Eyüpoglu<sup>7</sup> · Lingyang Hua<sup>8</sup> · Gilbert Youssef<sup>9</sup> · Patrick Y. Wen<sup>9</sup> · Daniel P. Cahill<sup>1</sup> · Christine Jungk<sup>2,3</sup> · Tareq A. Juratli<sup>1,7</sup> · Julie J. Miller<sup>1,4</sup>

Received: 11 September 2024 / Accepted: 3 October 2024 / Published online: 21 October 2024  
© The Author(s) 2024

## Abstract

**Purpose** Mutations in the *Isocitrate Dehydrogenase (IDH)* genes, *IDH1* or *IDH2*, define a group of adult diffuse gliomas associated with a younger age at diagnosis and better prognosis than IDH wild-type glioblastoma. Within IDH mutant gliomas, a small fraction of astrocytic tumors present with grade 4 histologic features and poor prognosis. In molecular studies, homozygous deletion of *CDKN2A/B* is independently predictive of poor prognosis and short survival. As a consequence, 2021 WHO classification now also recognizes this molecular feature, *CDKN2A/B* deletion, as sufficient for classifying an astrocytoma as IDH-mutant, WHO Grade 4, regardless of histological grading. Here, we investigate outcomes of patients with WHO Grade 4 IDH-mutant astrocytoma both with and without *CDKN2A/B* deletion, to compare these groups and evaluate clinical and radiographic factors that contribute to survival.

**Methods** We retrospectively identified 79 patients with IDH-mutant astrocytoma with *CDKN2A/B* deletion detected at initial diagnosis across five international institutions as well as a comparison group of 51 patients with IDH-mutant, astrocytoma, histologically Grade 4 without detectable *CDKN2A/B* deletion. We assembled clinical and radiographic features for all patients.

**Results** We find that *CDKN2A/B* deletion was associated with significantly worse overall survival (OS;  $p=0.0004$ ) and progression-free survival (PFS;  $p=0.0026$ ), with median OS of 5.0 years and PFS of 3.0 years, compared to 10.1 and 5.0 years for tumors with a grade 4 designation based only on histologic criteria. Multivariate analysis confirmed *CDKN2A/B* deletion as a strong negative prognosticator for both OS (HR = 3.51,  $p < 0.0001$ ) and PFS (HR = 2.35,  $p = 0.00095$ ). In addition, in tumors with *CDKN2A/B* deletion, preoperative contrast enhancement is a significant predictor of worse OS (HR 2.19, 95% CI 1.22–3.93,  $p = 0.0090$ ) and PFS (HR = 1.74, 95% CI = 1.02–2.97,  $p = 0.0420$ ).

**Conclusions** These findings underscore the severe prognostic impact of *CDKN2A/B* deletion in IDH-mutant astrocytomas and highlight the need for further refinement of tumor prognostic categorization. Our results provide a key benchmark of baseline patient outcomes for therapeutic trials, underscoring the importance of *CDKN2A/B* status assessment, in addition to histologic grading, in clinical trial design and therapeutic decision-making for IDH-mutant astrocytoma patients.

**Keywords** Glioma · *CDKN2A/B* homozygous deletion · Isocitrate dehydrogenase (IDH) · Astrocytoma · WHO grade 4

## Introduction

Mutations in the *Isocitrate Dehydrogenase (IDH)* 1 or 2 genes are defining genomic changes found in diffuse gliomas of younger adults [1–3]. Patients with IDH-mutant

astrocytomas generally have a better prognosis compared to those with IDH wild-type glioblastomas. However, molecular profiling has revealed subgroups of IDH-mutant astrocytomas that experience a more aggressive disease course. The most significant negative prognostic genetic

Ethan A. Wetzel, Amin I. Nohman, Christine Jungk, Tareq A. Juratli and Julie J. Miller contributed equally to this work.

Extended author information available on the last page of the article

alteration identified in IDH-mutant astrocytomas is homozygous deletion of *Cyclin-Dependent Kinase Inhibitor 2 A/B* (*CDKN2A/B*) [4]. *CDKN2A/B* deletion is one of the most common genetic alterations in cancer, found across multiple cancer types. This genetic locus encodes the p16 kinase inhibitor protein, which acts as a tumor suppressor by inhibiting the activity of Cyclin Dependent Kinase (CDK) 4/6 activity. In the absence of G1 regulation by p16, increased CDK4/6 activity leads to the hyperphosphorylation of retinoblastoma protein (Rb) and increased progression through the G1/S transition [5]. Therefore, the loss of this tumor suppressor removes a key inhibitory force on the cell cycle and leads to increased cell proliferation and malignant tumor growth.

In the context of IDH-mutant astrocytomas, *CDKN2A/B* deletion is infrequently observed at initial diagnosis, reported at a rate of ~10% [6, 7] and is rarely associated with lower histologic grade or oligodendroglial origin [4, 6]. At recurrence, particularly after radiation therapy [7], or with histologic grade progression, the frequency of *CDKN2A/B* deletion increases to 30–60% in IDH-mutant astrocytoma cases [7, 8]. Homozygous loss of *CDKN2A/B* is associated with a significantly worsened prognosis when detected at initial diagnosis, with a median survival of 3–5 years, compared to 7–12 years in *CDKN2A/B* wild-type tumors [4, 6].

The revised 2021 WHO classification now acknowledges *CDKN2A/B* deletion as a separate criterion sufficient to designate an astrocytoma as IDH-mutant, WHO Grade 4, whereas this classification previously was based solely on histological presence of palisading necrosis or microvascular proliferation within the tumor specimen [9]. This classification update signals the need for a continuing rounds of iterative prognostic refinement, as the poor prognostic tumors previously categorized as grade 2 or 3 are now included in the grade 4 cohort alongside histologic grade 4 tumors, and the relative prognostic relationship of histologic features independent of molecular features will require re-assessment.

This effort takes on additional urgency given the increasing translational potential of *CDKN2A/B* as a precision medicine target in IDH-mutant astrocytoma [10, 11]. Due to the limited available data on predictors of survival within this newly defined grade 4 subclass of IDH-mutant astrocytomas, we identified a large, international cohort of patients with IDH-mutant astrocytoma with *CDKN2A/B* homozygous deletion. In this study, we sought to characterize the overall and progression free survival (PFS) implications of *CDKN2A/B* homozygous deletion, in comparison to a control cohort of patients with histologic grade 4 disease without detectable *CDKN2A/B* deletion, and identify radiographic predictors of survival within patients harboring *CDKN2A/B* deletion. We confirm the strong negative

prognostic effect of *CDKN2A/B* deletion in a multi-centered cohort of patients with IDH-mutant astrocytoma, identify preoperative contrast enhancement as a novel predictor of shorter overall survival (OS) specifically within the *CDKN2A/B* deleted subgroup, and provide important historical reference comparison cohort data for future clinical trials enrolling patients with *CDKN2A/B* deleted, IDH-mutant astrocytoma.

## Methods

### Patient population and data collection

This study was approved by the Institutional Review Boards of all participating institutions. Patients with IDH-mutant glioma treated at Massachusetts General Hospital (MGH), the Dana Farber Cancer Institute (DFCI), University Hospital Heidelberg (UHH), University Hospital Dresden (UHD), and Fudan-Shanghai (FS) with available *CDKN2A/B* genotyping were identified and compiled for grouped analysis by the Massachusetts General Hospital Department of Neuro-oncology. All cases had a hotspot mutation in IDH1 or IDH2, as determined by immunohistochemistry (IHC), Sanger Sequencing, polymerase chain reaction, or next generation sequencing. Tumors designated as an astrocytoma, IDH-mutant, exhibit nuclear loss of ATRX expression by IHC, mutation in ATRX by next generation sequencing (NGS), and/or no evidence of deletion of chromosome 1p and 19q [12]. *CDKN2A/B* testing was done by panel (MGH), array comparative genomic hybridization (DFCI) or fluorescent in situ hybridization (FISH) (MGH, UHH, UHD, and FS). All *CDKN2A/B* genotyping was conducted on tissue retrieved from the patient's initial surgery. For comparison, the MGH IDH-mutant patient database was queried to assemble a cohort of patients with molecularly characterized astrocytoma, IDH-mutant, WHO Grade 4 based only on histologic criteria (microvascular proliferation or necrosis). All tumors in the comparison cohort had a hotspot mutation in IDH1 or IDH2, as determined by immunohistochemistry (IHC), Sanger Sequencing, polymerase chain reaction, or next generation sequencing. Similar to the *CDKN2A/B* deleted cohort, this consisted exclusively of astrocytomas, as determined by nuclear loss of ATRX expression by IHC, mutation in ATRX by NGS, and/or no evidence of deletion of chromosome 1p and 19q [12]. Of 67 Grade 4 astrocytoma, IDH-mutant, in the database, 54 cases without detectable homozygous deletion of *CDKN2A/B* were identified, with the remaining 13 cases with homozygous deletion of *CDKN2A/B* added to the deletion cohort. Three of 54 cases had hemizygous deletion of *CDKN2A/B* and were excluded. Of the remaining 51 cases in the

comparison cohort, *CDKN2A/B* deletion was not detectable by FISH and/or NGS in 15 cases; the *CDKN2A/B* status of the remaining 36 cases is unknown because the diagnosis was made prior to the time during which *CDKN2A2/B* testing became routine [9].

Clinical and radiographic data were extracted from the electronic medical record by clinical and research staff at participating institutions. Clinical data included age, sex, extent of surgical resection, date and type of upfront treatment, dates of progression, date of death, last known follow-up, and presence of preoperative enhancement. Extent of surgical resection was determined by the amount of residual T2 hyperintensity on the first post-operative MRI. Presence or absence of contrast-enhancement on imaging was determined by local neuroradiologist and reviewed by clinical and research staff at participating institutions. Tumors were considered to be positive for contrast-enhancement if both perpendicular areas on a single slice was at least 10 mm, in accordance with RANO 2.0 criteria [13]. Dates of progression were determined by the treating neuro-oncologist or neurosurgeon based on RANO 2.0 criteria [13].

### Survival and statistical analysis

Overall survival (OS) was defined as time from the date of initial surgery to the date of death from any cause. Progression-free survival (PFS) was defined as the time from the date of initial surgery to the date of progression or death. Patients without OS or PFS events were censored at last known follow-up.

Survival and all other statistical analyses were performed in GraphPad Prism and R Studio (Packages: “survival” version 3.5.8 and “survminer” 0.4.9). The Kaplan-Meier method was used to estimate OS and PFS. Median follow-up time was determined using the reverse Kaplan-Meier method. Comparisons between groups was assessed using the log-rank test.

Cox proportional hazard modeling was used to assess predictors of OS and PFS. Categorical variables were analyzed using the Chi-Square test while differences between means and medians were analyzed using a student’s unpaired T-test or ANOVA. For all analyses, a two-sided P-value of 0.05 was used to determine statistical significance.

## Results

### Clinical and radiologic characteristics

We retrospectively identified 79 patients with IDH-mutant astrocytoma with *CDKN2A/B* homozygous deletion treated among five distinct institutions (Massachusetts General

Hospital, USA ( $n=13$ ); Dana Farber Cancer Institute, USA ( $n=16$ ); University Hospital Heidelberg, Germany ( $n=34$ ); University Hospital Dresden, Germany ( $n=6$ ); and Fudan-Shanghai, China ( $n=10$ )) diagnosed between 1993 and 2023 (Table 1). Importantly, only cases in which *CDKN2A/B* deletion was identified at initial diagnosis were included. Patient demographics were similar among the cohorts, which was 58% male and had a median age at diagnosis of 36.2 years (Table 2), consistent with what has been previously reported [14, 15]. Of note, there were differences in patterns of administration of adjuvant therapy among institutions (Table 1).

As described in Methods, we concurrently identified 51 patients from Massachusetts General Hospital with astrocytoma, IDH-mutant, WHO grade 4, in which the grade 4 designation was made by histologic features alone to serve as a comparison cohort. The median age of this comparison group was 37.9 years (35.0 years for *CDKN2A/B* intact, 39.4 years for *CDKN2A/B* unknown) and it was 63% male. Overall, the demographics of *CDKN2A/B* deleted, *CDKN2/B* intact and *CDKN2/B* unknown cohorts are well matched (Table 2).

Patients in the comparison cohort with tumors that received a WHO Grade 4 designation based on histologic features only were more likely to have received adjuvant radiation, chemotherapy or combination of the two when compared to patients with *CDKN2A/B* - deleted tumors (Table 2). Notably, significantly more patients in the comparison cohort received adjuvant radiation and temozolomide combined compared to those in the *CDKN2A/B* - deleted cohort (100% vs. 81%,  $p=0.001$ ).

There was no significant difference in the incidence of preoperative contrast enhancement between the *CDKN2A/B* - intact cohort and the *CDKN2A/B* - unknown cohort (86.7% vs. 80.6%,  $p=0.61$ ). Interestingly, the incidence of preoperative contrast enhancement was significantly lower in the *CDKN2A/B* - deleted group compared to the comparison cohort (Tables 2 and 58.2% vs. 82.4%,  $p=0.004$ ).

### Impact of *CDKN2A/B* homozygous deletion on overall and Progression Free Survival

In the cohort of 79 patients with IDH-mutant astrocytoma with homozygous deletion of *CDKN2A/B* followed for a median of 5.1 years with 45 events observed, the median OS was 5.0 years. The median PFS in this cohort, based on 54 progression events, was 3.0 years. In contrast, the median OS of the comparison cohort of 51 patients with tumors that received a WHO Grade 4 designation based only on histologic features was 10.1 years, with the median OS in the 15 patients with IDH-mutant astrocytoma without detectable *CDKN2A/B* deletion undefined, followed for a median

**Table 1** Characteristics of patients with IDH-mutant astrocytoma with *CDKN2A/B* homozygous deletion across five institutions ( $N=79$ ). *Abbreviations* IQR, interquartile range; RT, radiation therapy; TMZ, temozolomide; *n/a*, not applicable

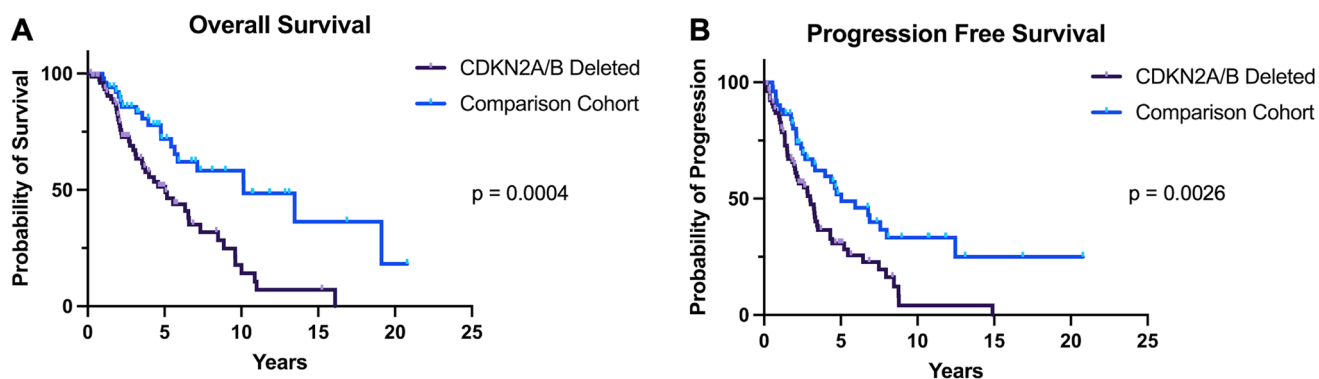
	Heidelberg CDKN2A/B Deleted N (%)	DFCI CDKN2A/B Deleted N (%)	Shanghai CDKN2A/B Deleted N (%)	MGH CDKN2A/B Deleted N (%)	Dresden CDKN2A/B Deleted N (%)	<i>p</i> -value
<b>Patient Demographics</b>						
N	34	16	10	13	6	
Male	22 (64%)	7 (40%)	5 (50%)	10 (77%)	2 (33%)	0.77
Median Age (IQR)	34.0 (28.8–44.3)	40.3 (31.2–50.7)	37.0 (32.5–43.3)	41.4 (33.0–48.8)	31.5 (28.0–35.8)	0.31
<b>Adjuvant Therapy</b>						
RT + TMZ	21 (61%)	15 (94%)	10 (100%)	13 (100%)	5 (83%)	0.02
TMZ Only	1 (3%)	0	0	0	0	
RT Only	5 (15%)	1 (6%)	0	0	0	
None	7 (21%)	0	0	0	1 (17%)	
<b>Radiographic Data</b>						
Contrast Enhancement	19 (56%)	11 (69%)	2 (20%)	10 (77%)	4 (67%)	0.06
<b>Extent of Resection</b>						
Gross Total Resection	11 (32%)	6 (38%)	9 (90%)	4 (30%)	5 (83%)	0.12
Subtotal Resection	19 (56%)	9 (56%)	1 (10%)	8 (62%)	0	
Biopsy (or unknown)	4 (12%)	1 (6%)	0	1 (8%)	1 (17%)	
<b>MGMT promoter status</b>						
Methylated	23 (68%)	10 (63%)	10 (100%)	10 (77%)	4 (67%)	0.06
Unmethylated	5 (15%)	5 (31%)	0	0	1 (16%)	
Unknown	6 (18%)	1 (6%)	0	3 (23%)	1 (16%)	
<b>Median Survival (years)</b>						
Overall Survival	4.0	11.0	Undefined	5.2	2.1	0.4225
Prog.free Survival	2.8	8.0	Undefined	2.2	2.0	0.3486
Median Follow-up	15.2	5.1	2.4	3.7	1.96	<i>n/a</i>

**Table 2** Cohort characteristics of patients with astrocytoma, IDH-mutant, WHO Grade 4, based on *CDKN2A/B* status. *Abbreviations* IQR, interquartile range; RT, radiation therapy; TMZ, temozolomide; NE, not evaluated; *n/a*, not applicable

	CDKN2A/B Deleted N (%)	Histologic grade 4 Comparison cohort N (%)	<i>p</i> -value
<b>Patient Demographics</b>			
N	79	51	
Male	46 (58%)	32 (63%)	0.60
Median Age (IQR)	36.2 (30–44)	37.9 (31–48.1)	0.11
<b>Adjuvant Therapy</b>			
RT + TMZ	64 (81%)	51 (100%)	0.067
TMZ Only	1 (1%)	0	
RT Only	6 (8%)	0	
None	8 (10%)	0	
<b>Radiographic Data</b>			
Contrast Enhancement	46 (58%)	42 (82%)	0.004
<b>Survival Data</b>			
Death	45 events (57%)	20 events (39%)	0.049
1st Progression	54 events (68%)	29 events (57%)	0.183
Median Follow-up	5.1	7.3	<i>n/a</i>

of 3.9 years, while the median OS of the 36 patients with unknown *CDKN2A/B* status was 10.1 years, followed for a median of 10.8 years. Similarly, the median PFS in the comparison cohort was 5.0 years (3.3 years for *CDKN2A/B* - intact and 5.9 years for *CDKN2A/B* - unknown). Although a small number of cases in the *CDKN2A/B* - unknown group may have *CDKN2A/B* deletion, the outcomes of this comparison cohort are similar to what has been reported for *CDKN2A/B* non-deleted cases by Shirahata et al. [4] and Appay et al. [6]. Compared to the tumors designated as grade 4 based on histologic features, *CDKN2A/B* homozygous deletion was associated with significantly shorter OS (HR 2.45, 95% CI 1.51–3.99,  $p=0.0004$ ) and PFS (HR 1.95, 95% CI 1.27–3.00,  $p=0.0026$ ) by log-rank analysis (Fig. 1A and B). Importantly, the significantly shortened OS and PFS observed in our large, international cohort are in agreement with what has been described previously for smaller, single country cohorts [4, 6], emphasizing generalizability to real-world scenarios.

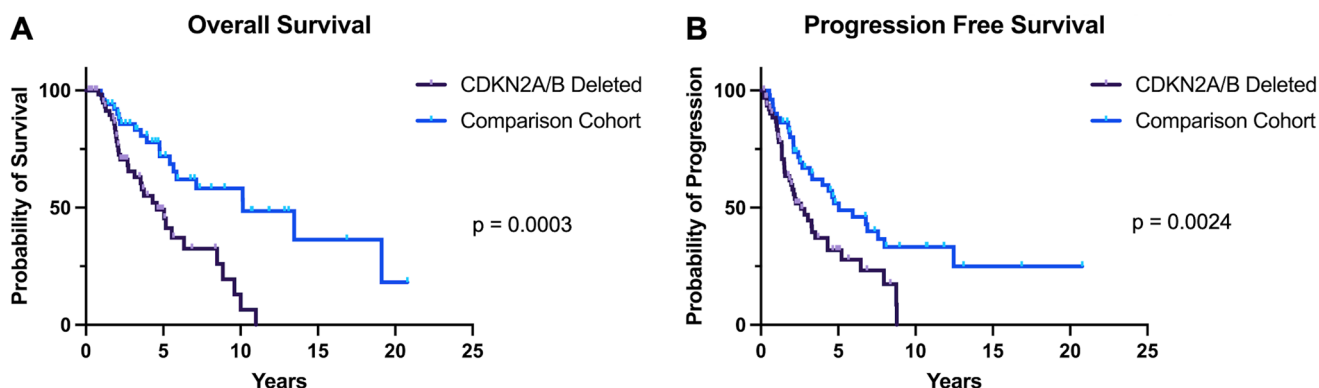
In a Cox Regression Multivariate Model adjusting for *CDKN2A/B* status, age, adjuvant treatment, extent of resection, and preoperative contrast enhancement, *CDKN2A/B* homozygous deletion remained strongly predictive of shorter OS (HR=3.51, 95% CI 1.92–6.38,  $p<0.0001$ ; Table 3). Similarly, *CDKN2A/B* homozygous deletion was



**Fig. 1** Kaplan-Meier curves of the effect of *CDKN2A/B* homozygous deletion on (A) overall survival and (B) progression-free survival. P-values represent significance level as determined by log-rank test

**Table 3** Results from the Cox regression analysis of the overall and progression free survival of multicentered cohort ( $N=130$ ). \* indicates  $p < 0.05$

	Overall survival			Progression free survival		
	HR	95% CI	<i>p</i> -value	HR	95% CI	<i>p</i> -value
<i>CDKN2A/B</i> Deletion	3.51	1.92–6.38	< 0.0001*	2.35	1.41–3.90	0.00095*
Age (Continuous)	1.03	1.01–1.06	0.0162*	1.03	1.01–1.05	0.00644*
Adjuvant Treatment	0.77	0.30–1.98	0.5857	0.86	0.36–2.1	0.73433
Extent of Resection (GTR)	0.87	0.51–1.48	0.6074	0.64	0.41–1.02	0.06284
Contrast Enhancement	2.43	1.24–4.75	0.0092*	1.73	1.03–2.93	0.04011*
Events	65			83		



**Fig. 2** Kaplan-Meier curves of the effect of *CDKN2A/B* homozygous deletion in patients who received adjuvant radiation and chemotherapy on (A) overall survival and (B) progression-free survival. P-values represent significance level as determined by log-rank test

also associated with shorter PFS when adjusting for the same variables (HR = 2.35, 95% CI 1.41–3.90,  $p=0.00095$ ; Table 3). Because our cohort was heterogeneously treated, we went on to investigate OS and PFS specifically in patients who received adjuvant radiation therapy and chemotherapy to control for a possible influence from treatment. We identified 64 (81%) patients in the *CDKN2A/B* deleted cohort and 51 (100%) patients in the comparison cohort who received upfront treatment with radiation followed by adjuvant chemotherapy (Table 1). Within this group, *CDKN2A/B* homozygous deletion remained significantly associated with shorter OS and PFS on both univariate (OS: 4.6 vs. 10.1 years,  $p=0.0003$ ; PFS: 2.6 vs. 5.0 years,  $p=0.0024$ ; Fig. 2) and multivariate analysis (OS: HR = 3.21, 95% CI

1.75–5.86,  $p < 0.0001$ ; PFS: HR = 2.25, 95% CI 1.35–3.74,  $p=0.0019$ ) (Table 4).

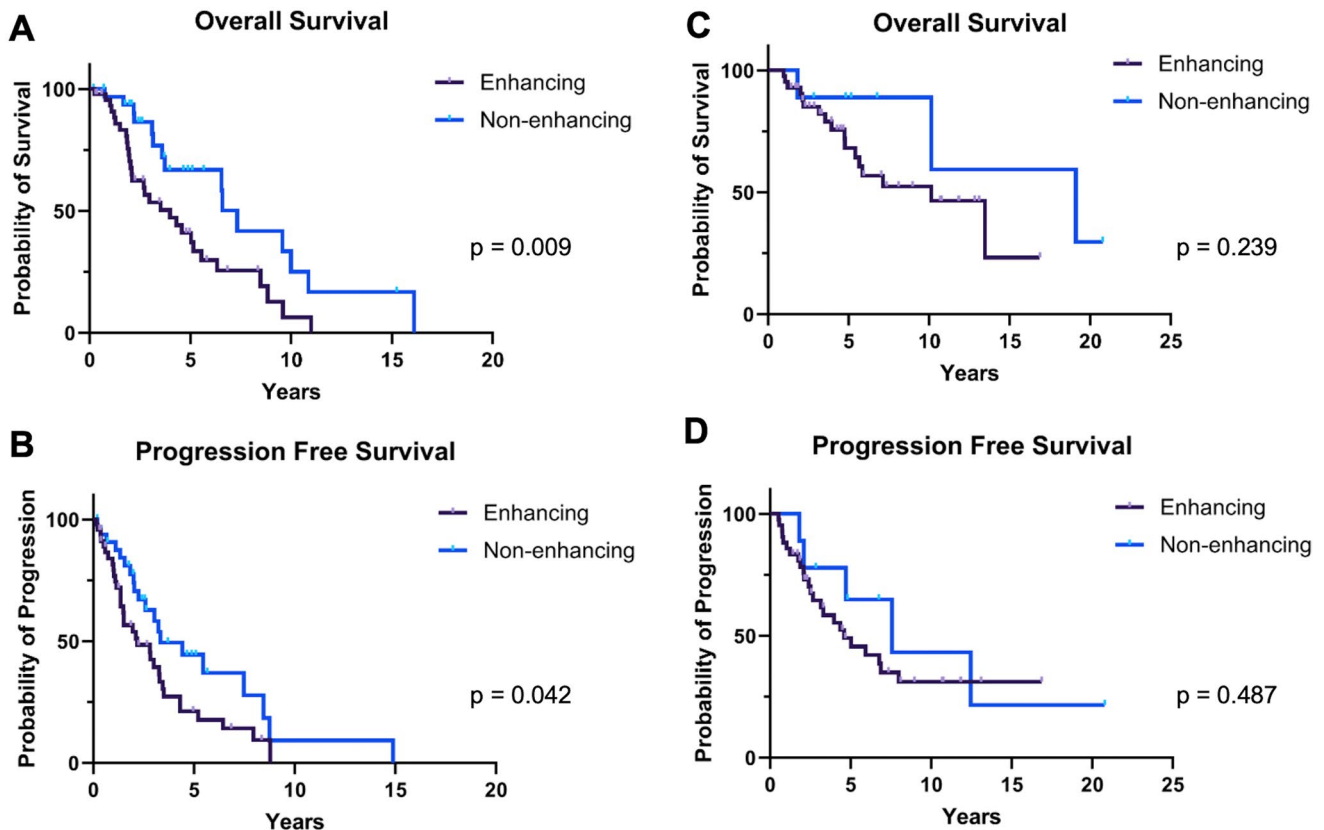
Altogether, these survival data demonstrate the strong negative prognostic effect of *CDKN2A/B* homozygous deletion in IDH-mutant astrocytoma, even when controlling for key variables that are associated with survival.

### Predictors of survival within *CDKN2A/B* deleted patients

Although the impact of *CDKN2A/B* homozygous deletion on survival has been well demonstrated in the existing literature, radiographic predictors of survival within this subset

**Table 4** Results from the Cox regression analysis of overall and progression free survival of patients treated with adjuvant radiation and chemotherapy ( $N=115$ ). \* indicates  $p < 0.05$ 

	Overall survival			Progression free survival		
	HR	95% CI	$p$ -value	HR	95% CI	$p$ -value
<i>CDKN2A/B</i> Deletion	3.21	1.75–5.86	< 0.0001*	2.25	1.35–3.74	0.0019*
Age (Continuous)	1.03	1.00–1.10	0.0462*	1.03	1.00–1.05	0.0223*
Extent of Resection (GTR)	0.83	0.47–1.45	0.5075	0.63	0.39–1.02	0.0616
Contrast Enhancement	2.04	1.10–3.94	0.0333*	1.57	0.93–2.65	0.0927
Events	58			76		

**Fig. 3** Kaplan-Meier curves of the effect of pre-operative contrast enhancement on survival outcomes of patients with tumors with *CDKN2A/B* deletion (**A / B**) and comparison cohort with grade 4

determination made on histologic grounds (**C / D**). P-values represent significance level as determined by log-rank test

of patients have not been thoroughly explored. Due to the previously reported association between preoperative contrast enhancement (CE) and poor survival outcomes in IDH-mutant glioma [16–18], we investigated whether CE was prognostic in our *CDKN2A/B* deleted cohort. CE, present in 46 (58%) of cases with *CDKN2A/B* homozygous deletion, was associated with shorter OS (4.0 vs 7.3 years, HR 2.19, 95% CI 1.22–3.93,  $p=0.0090$ ) and PFS (2.2 vs. 3.3 years, HR = 1.74, 95% CI = 1.02–2.97,  $p=0.0420$ ) (Fig. 3). CE remained significantly associated with worse OS, but not PFS after adjusting for frontline treatment and age in Cox regression analysis (OS: HR = 2.49, 95% CI 1.17–5.28,  $p=0.0176$ ; PFS: HR = 1.81, 95% CI = 0.98–3.36,  $p=0.0588$ ) (Table 5). In contrast, in the comparison cohort

of tumors designated as WHO grade 4 by histologic features only, there was no association between preoperative contrast-enhancement and OS (HR 1.95, 95% CI 0.64–5.94,  $p=0.239$ ) or PFS (HR 1.40, 95% CI 0.59–3.34,  $p=0.487$ ). Overall, these data indicate that preoperative contrast-enhancement on MRI performed at initial diagnosis may be a significant predictor of shorter OS specifically with patients with *CDKN2A/B* deleted, IDH-mutant astrocytoma.

**Table 5** Results from cox regression analysis of overall and progression free survival within patients with *CDKN2A/B* deletion ( $N = 79$ ). \* indicates  $p < 0.05$ 

	Overall survival			Progression Free survival		
	HR	95% CI	<i>p</i> -value	HR	95% CI	<i>p</i> -value
Contrast Enhancement	2.49	1.17–5.28	0.0176*	1.81	0.98–3.36	0.0588
Age (Continuous)	1.01	0.98–1.05	0.5297	1.02	0.99–1.05	0.2675
Adjuvant Treatment	0.87	0.32–2.41	0.7954	0.97	0.38–2.50	0.9537
Extent of Resection (GTR)	0.81	0.42–1.58	0.5418	0.74	0.41–1.36	0.3391
Events	45			54		

## Discussion

Here, we present the clinical outcomes of a large, multi-centered cohort of patients with astrocytoma, IDH-mutant, WHO grade 4. Across five institutions (Massachusetts General Hospital, Dana Farber Cancer Institute, University Hospital Heidelberg, University Hospital Dresden, and Fudan-Shanghai, China), we identified 79 patients with IDH-mutant astrocytoma found to have *CDKN2A/B* deletion at initial diagnosis. In this geographically diverse cohort, we report a median OS of 5.0 years and a PFS of 3.0 years, consistent with what has been reported previously [4, 6]. These outcomes contrast starkly with those observed in our comparison cohort of patients with IDH-mutant astrocytoma with WHO grade 4 designations made on histologic grounds, in which median OS and PFS were 10.1 and 5.0 years, respectively. After adjusting for upfront treatment, age, and preoperative contrast enhancement, *CDKN2A/B* homozygous deletion remains an exceedingly strong negative prognosticator of both OS and PFS.

Importantly however, despite the shared designation of IDH-mutant astrocytoma, grade 4 for tumors with *CDKN2A/B* deletion and those with histological evidence of necrosis and/or microvascular proliferation, we show that these two pathways to the grade 4 designation are not prognostically equivalent. Similarly, Appay et al., 2019 examined a large cohort of IDH-mutant astrocytoma patients and found that the presence of necrosis and/or microvascular proliferation was only prognostically significant in the absence of *CDKN2A/B* deletion, suggesting that the presence of the *CDKN2A/B* homozygous deletion necessitates a fundamental change in the grading of these tumors [6]. This highlights the nuance of transitioning from grading cohorts solely defined by histologic features to the inclusion of molecular features to make accurate prognostic predictions, emphasizing the need to iteratively re-define and re-assess prognostic cohorts, and uncover more molecular features to further modernize the classification system. It is entirely possible that grade 4 histologic features were prognostic in the past because they identified cohorts more likely to be *CDKN2A/B* deleted, but are not prognostic in-isolation, in the absence of detectable molecular alterations.

Although this study was limited by its retrospective nature, we attempted to control for the effect of heterogeneous upfront treatment between patients and institutions by including an analysis of a subset of patients who received radiation and adjuvant temozolomide in the upfront setting. The study was also limited by the fact that the *CDKN2A/B* status is unknown in many cases within the comparison cohort. Nevertheless, this comparison cohort clearly emphasizes the concept that histologic features more broadly and heterogeneously define patient cohorts, when compared to narrowly-defined cohorts derived using molecular features, which impacts accurate prognostication.

Furthermore, our study examined radiographic predictors of survival within the IDH-mutant astrocytoma *CDKN2A/B* deleted subgroup, identifying preoperative contrast enhancement as a predictor of worsened OS. Importantly, we identify contrast enhancement as a prognostically relevant variable within this patient population. A recurring theme within studies of patients with IDH-mutant gliomas is that the variables traditionally thought to influence outcomes, such as age and presence of contrast-enhancement on imaging, require iterative re-assessment in the current era of molecular diagnosis, with each update of cohort definition. In particular, the literature is mixed as to whether CE and survival are associated in IDH-mutant astrocytoma. Our data illuminate a likely explanation for these mixed findings, suggesting that the prognostic relationship may not be static between molecular subgroups. Although our analysis is limited by small number of non-enhancing tumors in the *CDKN2A/B* intact subgroup, we find that pre-operative CE serves as a negative prognostic factor primarily within the *CDKN2A/B* deleted, IDH-mutant astrocytoma subgroup.

Overall, this study of the largest cohort of patients with IDH-mutant astrocytoma with *CDKN2A/B* deletion published to date aligns with previous work demonstrating the strong negative prognostic impact of *CDKN2A/B* deletion in IDH-mutant astrocytoma [4, 6, 7, 19, 20], reinforcing the significant negative prognostic impact of *CDKN2A/B* deletion in patients with IDH-mutant astrocytoma across a large, multi-centered cohort. Critically for the future, the outcome data reported herein serve as a key reference cohort for future clinical trial design as precision medicine

targets for this therapeutically orphaned patient population are explored.

**Acknowledgements** We thank our patients for their donation of critical research materials.

**Author contributions** JJM, TAJ and CJ conceived of the project, designed the project and assembled resources. EW, AIN, ALH, DR, IYE, LH, GY, CJ, TAJ and JJM collected data. EW, AWU, PYW, DPC, CJ, TAJ and JJM analyzed and interpreted data. EW and JJM wrote the main manuscript text. All authors reviewed the manuscript.

**Funding** This work was supported by NINDS K08NS119796 and Seeman Family MGH Scholar Fund.

**Data availability** No datasets were generated or analysed during the current study.

## Declarations

**Competing interests** D. P. C reports grants from NIH and Tawingo Fund during the conduct of the study; financial compensation from Servier, Boston Scientific and Pyramid Biosciences for advisory input. PYW reports research support from Astra Zeneca, Black Diamond, Bristol Meyers Squibb, Celgene, Chimerix, Eli Lilly, Erasca, Genentech/ Roche, Kazia, MediciNova, Merck, Novartis, Nuvation Bio, Servier, Vascular Biogenics, VBI Vaccines; personal fees from Astra Zeneca, Black Diamond, Celularity, Chimerix, Day One Bio, Genenta, Glaxo Smith Kline, Merck, Mundipharma, Novartis, Novocure, Nuvation Bio, Prelude Therapeutics, Sapience, Servier, Sagimet, Vascular Biogenics, VBI Vaccines. T.A.J. received honoraria from CSL Behring. J.J.M. reports grants from the National Institute of Neurological Diseases and Stroke, American Cancer Society, Seeman Family Funds, National Cancer Institute, and MGH Transformative Scholar Award during the conduct of the study; personal fees from Servier.

**Open Access** This article is licensed under a Creative Commons Attribution-NonCommercial-NoDerivatives 4.0 International License, which permits any non-commercial use, sharing, distribution and reproduction in any medium or format, as long as you give appropriate credit to the original author(s) and the source, provide a link to the Creative Commons licence, and indicate if you modified the licensed material. You do not have permission under this licence to share adapted material derived from this article or parts of it. The images or other third party material in this article are included in the article's Creative Commons licence, unless indicated otherwise in a credit line to the material. If material is not included in the article's Creative Commons licence and your intended use is not permitted by statutory regulation or exceeds the permitted use, you will need to obtain permission directly from the copyright holder. To view a copy of this licence, visit <http://creativecommons.org/licenses/by-nc-nd/4.0/>.

## References

- Parsons DW, Jones S, Zhang X, Lin JC-H, Leary RJ, Angenendt P et al (2008) An integrated genomic analysis of human glioblastoma multiforme. *Science* 321(5897):1807–1812. <https://doi.org/10.1126/science.1164382>
- Yan H, Parsons DW, Jin G, McLendon R, Rasheed BA, Yuan W et al (2009) IDH1 and IDH2 mutations in gliomas. *N Engl J Med* 360(8):765–773. <https://doi.org/10.1056/NEJMoa0808710>
- Miller JJ, Gonzalez Castro LN, McBrayer S, Weller M, Cloughesy T, Portnow J et al (2023) Isocitrate dehydrogenase (IDH) mutant gliomas: a Society for Neuro-Oncology (SNO) consensus review on diagnosis, management, and future directions. *Neuro Oncol* 25(1):4–25. <https://doi.org/10.1093/neuonc/noac207>
- Shirahata M, Ono T, Stichel D, Schrimpf D, Reuss DE, Sahm F et al (2018) Novel, improved grading system(s) for IDH-mutant astrocytic gliomas. *Acta Neuropathol* 136(1):153–166. <https://doi.org/10.1007/s00401-018-1849-4>
- Sherr CJ (2016) A New Cell-Cycle Target in Cancer - Inhibiting cyclin D-Dependent kinases 4 and 6. *N Engl J Med* 375(20):1920–1923. <https://doi.org/10.1056/NEJMp1612343>
- Appay R, Dehais C, Maurage CA, Alentorn A, Carpentier C, Colin C et al (2019) CDKN2A homozygous deletion is a strong adverse prognosis factor in diffuse malignant IDH-mutant gliomas. *Neuro Oncol* 21(12):1519–1528. <https://doi.org/10.1093/neuonc/noz124>
- Kocakavuk E, Anderson KJ, Varn FS, Johnson KC, Amin SB, Sulman EP et al (2021) Radiotherapy is associated with a deletion signature that contributes to poor outcomes in patients with cancer. *Nat Genet* 53(7):1088–1096. <https://doi.org/10.1038/s41588-021-00874-3>
- Barthel FP, Johnson KC, Varn FS, Moskalik AD, Tanner G, Kocakavuk E et al (2019) Longitudinal molecular trajectories of diffuse glioma in adults. *Nature* 576(7785):112–120. <https://doi.org/10.1038/s41586-019-1775-1>
- Louis DN, Perry A, Wesseling P, Brat DJ, Cree IA, Figarella-Branger D et al (2021) The 2021 WHO classification of tumors of the Central Nervous System: a summary. *Neuro Oncol* 23(8):1231–1251. <https://doi.org/10.1093/neuonc/noab106>
- Nasser AM, Melamed L, Wetzel EA, Chang JC, Nagashima H, Kitagawa Y et al (2024) CDKN2A/B homozygous deletion sensitizes IDH-Mutant glioma to CDK4/6 inhibition. *Clin Cancer Res* 30(14):2996–3005.
- Fortin Ensign SP, Jenkins RB, Giannini C, Sarkaria JN, Galanis E, Kizilbash SH (2023) Translational significance of CDKN2A/B homozygous deletion in isocitrate dehydrogenase-mutant astrocytoma. *Neuro Oncol* 25(1):28–36. <https://doi.org/10.1093/neuonc/noac205>
- Reuss DE (2023) Updates on the WHO diagnosis of IDH-mutant glioma. *J Neurooncol* 162(3):461–469. <https://doi.org/10.1007/s11060-023-04250-5>
- Wen PY, van den Bent M, Youssef G, Cloughesy TF, Ellingson BM, Weller M et al (2023) RANO 2.0: update to the Response Assessment in Neuro-Oncology Criteria for High- and low-Grade gliomas in adults. *J Clin Oncol* 41(33):5187–5199. <https://doi.org/10.1200/JCO.23.01059>
- Brat DJ, Verhaak RG, Aldape KD, Yung WK, Salama SR, Cooper LA et al (2015) Comprehensive, Integrative Genomic Analysis of Diffuse Lower-Grade Gliomas. *N Engl J Med* 372(26):2481–2498. <https://doi.org/10.1056/NEJMoa1402121>
- Eckel-Passow JE, Lachance DH, Molinaro AM, Walsh KM, Decker PA, Sicotte H et al (2015) Glioma groups based on 1p/19q, IDH, and TERT promoter mutations in tumors. *N Engl J Med* 372(26):2499–2508. <https://doi.org/10.1056/NEJMoa1407279>
- Jonsson P, Lin AL, Young RJ, DiStefano NM, Hyman DM, Li BT et al (2019) Genomic Correlates of Disease Progression and Treatment Response in prospectively characterized gliomas. *Clin Cancer Res* 25(18):5537–5547. <https://doi.org/10.1158/1078-0432.CCR-19-0032>
- Hempel JM, Brendle C, Bender B, Bier G, Skardelly M, Gepfner-Tuma I et al (2018) Contrast enhancement predicting survival in integrated molecular subtypes of diffuse glioma: an observational cohort study. *J Neurooncol* 139(2):373–381. <https://doi.org/10.1007/s11060-018-2872-y>

18. Juratli TA, Tummala SS, Riedl A, Daubner D, Hennig S, Penson T et al (2019) Radiographic assessment of contrast enhancement and T2/FLAIR mismatch sign in lower grade gliomas: correlation with molecular groups. *J Neurooncol* 141(2):327–335. <https://doi.org/10.1007/s11060-018-03034-6>
19. Kocakavuk E, Johnson KC, Sabedot TS, Reinhardt HC, Noushmehr H, Verhaak RGW (2023) Hemizygous CDKN2A deletion confers worse survival outcomes in IDHmut-noncodel gliomas. *Neuro Oncol* 25(9):1721–1723. <https://doi.org/10.1093/neuonc/noad095>
20. Hickman RA, Gedvilaite E, Ptashkin R, Reiner AS, Cimera R, Nandakumar S et al (2023) CDKN2A/B mutations and allelic-specific alterations stratify survival outcomes in IDH-mutant astrocytomas. *Acta Neuropathol* 146(6):845–847. <https://doi.org/10.1007/s00401-023-02639-0>

**Publisher's note** Springer Nature remains neutral with regard to jurisdictional claims in published maps and institutional affiliations.

## Authors and Affiliations

Ethan A. Wetzel<sup>1</sup> · Amin I. Nohman<sup>2,3</sup> · Annie L. Hsieh<sup>4</sup> · David Reuss<sup>5,6</sup> · Andreas W. Unterberg<sup>2,3</sup> · Ilker Y. Eyüpoglu<sup>7</sup> · Lingyang Hua<sup>8</sup> · Gilbert Youssef<sup>9</sup> · Patrick Y. Wen<sup>9</sup> · Daniel P. Cahill<sup>1</sup> · Christine Jungk<sup>2,3</sup> · Tareq A. Juratli<sup>1,7</sup> · Julie J. Miller<sup>1,4</sup>

✉ Julie J. Miller  
julie.miller@mgh.harvard.edu

<sup>1</sup> Translational Neuro-Oncology Laboratory, Department of Neurosurgery, Massachusetts General Hospital, Harvard Medical School, Boston, MA, USA

<sup>2</sup> Department of Neurosurgery, University Hospital Heidelberg, Heidelberg, Germany

<sup>3</sup> Department of Neurosurgery, Medical Faculty, Heidelberg University, Heidelberg, Germany

<sup>4</sup> Pappas Center for Neuro-Oncology, Department of Neurology, Massachusetts General Hospital, Harvard Medical School, Boston, MA, USA

<sup>5</sup> Department of Neuropathology, Institute of Pathology, Heidelberg University Hospital, Heidelberg, Germany

<sup>6</sup> Clinical Cooperation Unit Neuropathology, German Cancer Research Center (DKFZ), German Consortium for Translational Cancer Research (DKTK), Heidelberg, Germany

<sup>7</sup> Faculty of Medicine, Department of Neurosurgery, TU Dresden, Dresden, Germany

<sup>8</sup> Hospital of Huashan, Fudan University, Shanghai, China

<sup>9</sup> Center for Neuro-Oncology, Dana-Farber Cancer Institute, Harvard Medical School, Boston, MA, USA