Check for updates

Gyroscopic Radiosurgery: Clinical Experience and Prospective Analysis of over 500 Treated Tumors

Antonio Santacroce[1-3], Alexander Muacevic[1], Nadja Kohlhase[1], Dochka Eftimova[1], Theresa Hofmann[1], Matthias Sammer[1], Annabel Graser[1,4], Markus Kufeld[1], Christoph Fürweger[1,5], Felix Ehret[1,6,7]

■ BACKGROUND: **Stereotactic radiosurgery plays a significant role in the treatment of various benign and malignant tumors of the central nervous system. Recently, the first self-shielding treatment platform for gyroscopic radiosurgery (GRS) was introduced. Herein, we report our experience with GRS treatment of the first 541 tumors in a prospective setting.**

■ METHODS: **This study enrolled patients who underwent GRS for intracranial tumors. Patient, treatment, and outcome data were prospectively collected and analyzed. Only patients with at least 1 imaging and clinical follow-up were included in this analysis. Volumetric assessments and major toxicity are presented.**

■ RESULTS: **A total of 491 patients were treated between 2021 and 2024. Of those, 382 patients harboring 541 tumors underwent at least 1 imaging and clinical follow-up. The majority of tumor entities treated were vestibular schwannomas (196), brain metastases (188), and meningiomas (113). The median prescription dose for brain metastases was 20 Gy. For meningiomas and vestibular schwannomas, the median prescription doses were 15 and 13 Gy, respectively. Analysis of dosimetric performance showed that GRS treatments are highly conformal, achieving steep dose gradients. The median imaging follow-up was 10.6 months. Volumetry of the treated targets demonstrated an early treatment response with either volume reduction or stability for most tumors.**

■ CONCLUSIONS: **The early results of this prospective study, show the efficacy and safety of the new self-shielding treatment platform. Due to the limited follow-up of this analysis, future studies including long-term outcome data are needed.**

INTRODUCTION

Among the various treatment techniques in neurosurgery and radiation oncology, stereotactic radiosurgery (SRS) has emerged as a primary treatment option in the management of various tumors of the central nervous system.[1-3] Although brain metastases are 1 of the most important indications for SRS, numerous studies have also reported favorable

Key words
- Brain Metastasis
- Gyroscopic Radiosurgery
- Meningioma
- Radiosurgery
- Stereotactic Radiosurgery
- Vestibular Schwannoma
- ZAP-X

Abbreviations and Acronyms
CI: Conformity index
GI: Gradient index
GK: Gamma Knife
GRS: Gyroscopic radiosurgery
HI: Homogeneity index
Linac: Linear accelerator
MU: Monitor unit
nCI: New conformity index
RN: Radiation necrosis
RRS: Robotic radiosurgery
SRS: Stereotactic radiosurgery
TV: Target volume
WBRT: Whole-brain radiotherapy
WHO: World Health Organization

From the [1]European Radiosurgery Center Munich, Munich, Germany; [2]Department of Neurosurgery, St. Barbara-Klinik Hamm-Heessen, Hamm, Germany; [3]Department of Medicine, Faculty of Health, Witten/Herdecke University, Witten, Germany; [4]Department of Urology, LMU University Hospital, LMU Munich, Munich, Germany; [5]Department of Stereotaxy and Functional Neurosurgery, University Hospital Cologne, Cologne, Germany; [6]Charité — Universitätsmedizin Berlin, Corporate Member of Freie Universität Berlin and Humboldt-Universität zu Berlin, Department of Radiation Oncology, Berlin, Germany; and [7]German Cancer Consortium (DKTK), partner site Berlin, a partnership between DKFZ and Charité — Universitätsmedizin Berlin, Berlin, Germany

To whom correspondence should be addressed: Antonio Santacroce, M.D. [E-mail: antoniosantacroce@msn.com]

Citation: World Neurosurg. (2026) 205:124684.
http://doi.org/10.1016/j.wneu.2025.124684

*Journal homepage: **www.journals.elsevier.com/world-neurosurgery***

*Available online: **www.sciencedirect.com***

1878-8750/© 2025 The Author(s). Published by Elsevier Inc. This is an open access article under the CC BY license (http://creativecommons.org/licenses/by/4.0/).

outcomes for other conditions, including meningiomas, vestibular schwannomas, and arteriovenous malformations.[2-4] SRS can be delivered by properly trained neurosurgeons and radiation oncologists with many devices. These include the Gamma Knife (GK), CyberKnife (robotic radiosurgery [RRS]), and dedicated stereotactic linear accelerators (linac). More recently, the first self-shielding gyroscopic radiosurgery (GRS) device, enabling SRS without a vault, was introduced into daily practice.[5] An increasing number of early technical and clinical reports indicate that GRS is being used by various centers in daily clinical practice, and the range of diseases being treated with it is expanding. This range now includes not only brain metastases but also benign skull base tumors and, more recently, trigeminal neuralgia.[5-13] Given the limited data on GRS, this report aims to provide an update on our experience based on a cohort of more than 380 patients with more than 500 tumors, as determined by imaging-volumetric analysis and toxicity assessment after GRS.

MATERIALS AND METHODS

Patients enrolled in the prospective study entitled "Self-Shielding Gyroscopic Radiosurgery—a First Prospective Observational Study and Retrospective Comparison" (GRAY I) (clinical trial identifier: DRKS00025820) and treated with GRS for a benign or malignant intracranial tumor between December 2021 and December 2024 with at least 1 clinical and imaging follow-up available until March 2025 were included in this analysis.[6] Two patients treated for trigeminal neuralgia, 9 treated for arteriovenous malformations, and 1 treated for an arteriovenous fistula were excluded from the analysis. All treatments were performed with the ZAP-X (ZAP Surgical Systems Inc., San Carlos, CA, USA) GRS platform in a single session. There were no fractionated treatments. Treatment planning was performed using various versions of the ZAP-X treatment planning system (version 1.8.55—1.10.1).

Each patient underwent a planning computed tomography scan, which was fused with contrast-enhanced magnetic resonance imaging. Treatment immobilization was achieved using a noninvasive thermoplastic mask. For patients suffering from brain metastases and uveal melanomas, the first follow-up was usually performed 3 months after the treatment. Patients treated for benign lesions had their first follow-up 6 months after GRS.

As previously reported, toxicity was assessed using the Common Terminology Criteria for Adverse Events version 5.0. The House-Brackmann score was used separately to assess morbidity related to the facial nerve. Patient satisfaction with the treatment experience was graded at each follow-up visit using a 5-point Likert scale ("1" to "5", "1" being "very satisfied" and "5" being '"very disappointed").[5] Treatment indices defining conformity index (CI), new conformity index (nCI), homogeneity index (HI), and dose gradient index (GI) were calculated as previously described.[5,6,14-16]

Patient, tumor, and treatment characteristics were prospectively collected. All targets underwent volumetric assessment at each follow-up visit. For patients with multiple brain metastases, the target volume (TV) of the metastases treated was pooled in a single volume before and after treatment. In the event of a new brain metastasis diagnosis, further GRS treatment was performed, and volumetric assessment was conducted according to the same criteria but separately analyzed from previous treatments. In case of multiple benign tumors, each target was counted separately and volumetrically assessed thereafter. Total treatment time was defined as the duration from the start of the patient setup process until the patient was removed from the machine. Volumetric assessment was performed with OsiriX MD (Certificate of Conformance [ID 170770516]). Volume shrinkage was defined as a reduction in volume of at least 10% for benign tumors and at least 20% for malignant tumors. The evaluation of volume at follow-up was based on a careful analysis of imaging studies and clinical examinations performed by the attending physician in charge of the patient and reviewed by the first author. Figures were created using Microsoft Excel (Microsoft, Redmond, WA, USA) and GraphPad Prism 8.01 (GraphPad Software, San Diego, CA, USA). This study was approved by the local institutional review board (21—1018).

RESULTS

A total of 491 patients were enrolled between December 2021 and December 2024. Three hundred eighty-two patients (155 males and 227 females) and a total of 541 tumors were included in this analysis, as described in **Figure 1**. The majority of targets treated during the analyzed period were benign lesions (61%), followed by brain metastases and uveal melanomas, which comprised 35% and 3%, respectively. Of the entire cohort, vestibular schwannomas represented 36%, meningiomas 21%, and pituitary adenomas 4%. The median age at the time of treatment was 60.2 years. Most patients were treated for a single target (88%), with a maximum of 27 targets being treated in 1 patient with multiple brain metastases over the course of 3 treatments. The median prescribed doses for brain metastases, vestibular schwannomas, and meningiomas were 20 Gy, 13 Gy, and 15 Gy, respectively. The median dosimetric performance indices were 1.19 (CI), 1.23 (nCI), 1.85 (HI), and 3.01 (GI). The median coverage was 97.4%. The median imaging follow-up was 10.6 months (range: 2.4—26 months). Volumetric assessment of treated tumors is shown in **Figure 2**.

The median total treatment time was 46 minutes, which increased with the number of beams, monitor units (MUs), and isocenters (**Figures 3**, **4**, and **5**, all $P < 0.01$). Most treatments were completed in an hour or less (76%). An exemplary treatment plan is shown in **Figure 6**. Patient and tumor characteristics are summarized in **Table 1**, and treatment characteristics are

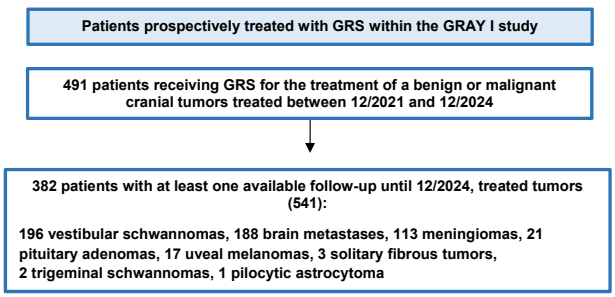

Figure 1. Details of enrolled and analyzed patients with treatment targets.

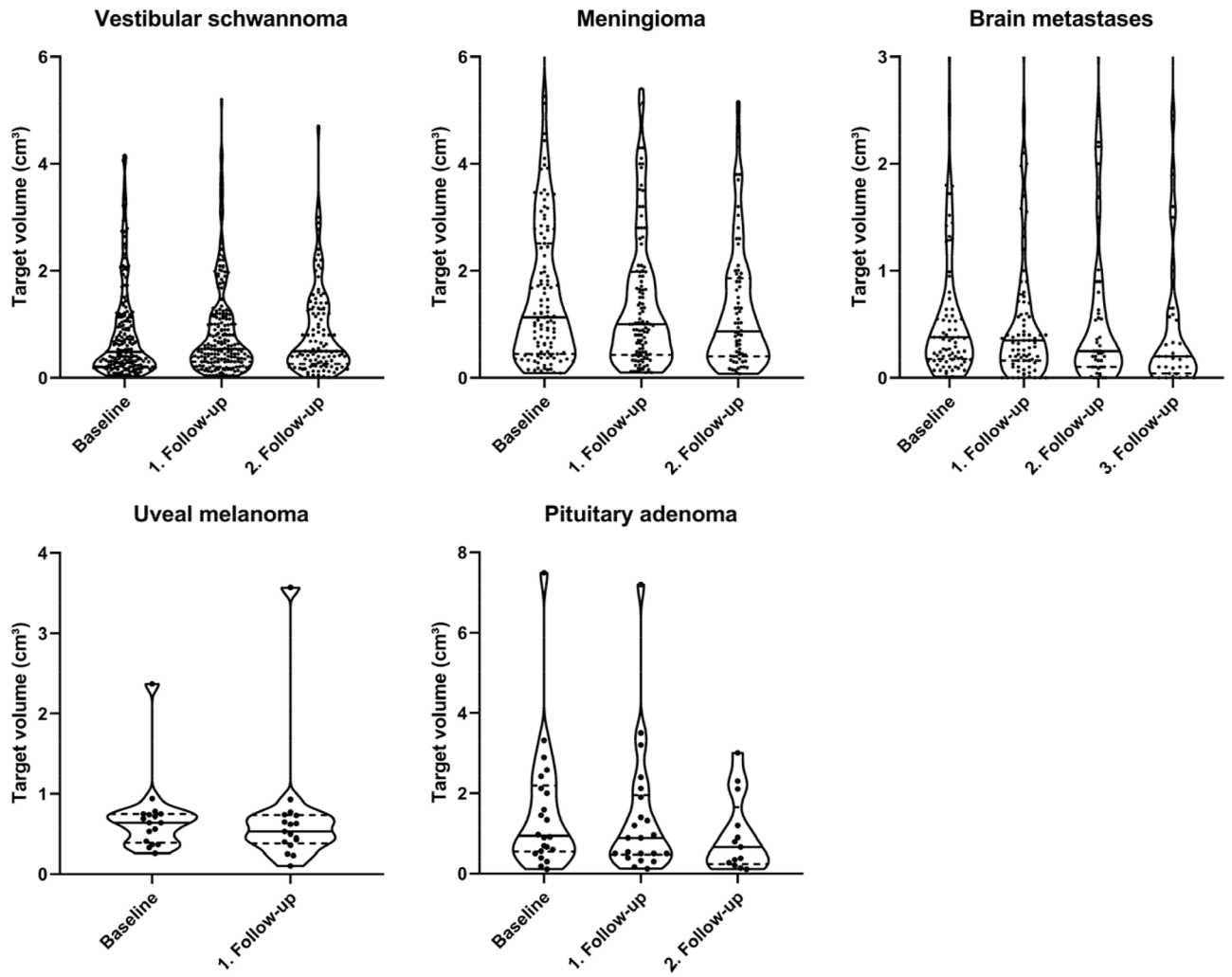

Figure 2. Volumetry of brain metastases, vestibular schwannomas, uveal melanomas, meningiomas, and pituitary adenomas before and after treatment.

summarized in Table 2. A total of 317 patients agreed to report their overall treatment experience with GRS (response rate 83.0%). Complications were observed in 29 patients (7.6%), as detailed in Table 3. Most patients were "very satisfied" (285 patients, 89.9%) or "satisfied" (18 patients, 5.7%). Twelve patients reported a "neutral" satisfaction score (3.8%), and 2 patients (0.6%) were "very disappointed". The first disappointed patient complained of worsening tinnitus, which was already present before GRS for a vestibular schwannoma, while the second patient reported hearing worsening and severe vertigo 6 months after treatment, which partially improved 18 months after GRS for vestibular schwannoma.

Intracranial Meningiomas

Thirteen patients underwent GRS for histologically confirmed World Health Organization (WHO) grade 2 meningiomas. The remaining patients were diagnosed with either WHO grade 1 meningiomas or imaging-defined meningiomas without histological confirmation. The median TV was 1.6 cc. The median imaging follow-up period was 12.6 months (range: 1.5–34.7 months). Among the 113 meningiomas treated with GRS, volume shrinkage was observed in 33 cases (29.2%). Edema was observed in 9 cases (7.9%) after GRS. Three cases resolved following a 10-day course of dexamethasone treatment, the others did not require any further therapy. Neither generalized nor focal seizures were observed 6 or 18 months after GRS. No local recurrence was observed during the available short-term follow-up. An out-of-field recurrence of an imaging-defined meningioma was treated approximately 1 year after GRS. No tumor progression was observed after GRS for WHO grade 2 meningiomas.

Vestibular Schwannomas

The median imaging follow-up was 12.6 months (range: 1.6–32.3 months), and the median volume at the time of treatment was

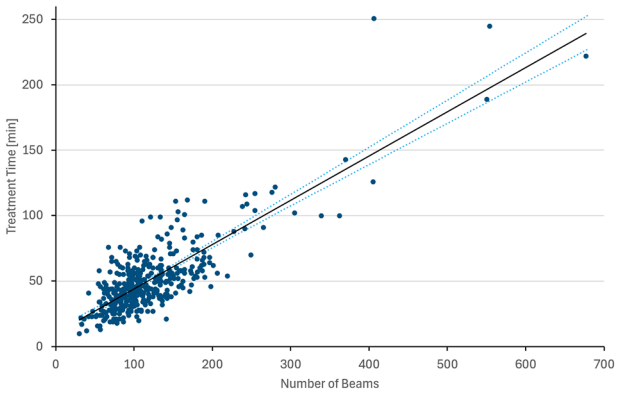

Figure 3. Total treatment time versus the number of beams.

0.7 cc (see Table 1). A volume shrinkage was observed in 42 tumors after GRS (21.4%). Recorded adverse events grade $\geq$ 3 comprised 8 cases of vertigo (grade 3 in 2 patients and grade 2 and lower in 6 patients before GRS), which improved to grade 2 (1 patient) and grade 1 (3 patients) at the last available follow-up. We report 3 cases of grade 3 tinnitus. One temporary case of grade 3 tinnitus improved to grade 2 at the last follow-up. One patient treated for a recurrent vestibular schwannoma after RRS developed a new facial nerve disorder/palsy (rated House-Brackmann grade V) from House-Brackmann grade IV prior to GRS. One patient with primary GRS for a vestibular schwannoma developed a temporary facial nerve disorder/palsy at the first follow-up (rated House-Brackmann grade V), which was not present before GRS. The facial nerve disorder improved to House-Brackmann grade IV after a year, then to House-Brackmann grade III after 18 months. One patient developed an acute facial palsy (rated House-Brackmann Grade IV), which improved to House-Brackmann grade II 1 year after GRS. The overall rate of facial nerve palsy was 1.5%. One patient developed a facial tic with dyskinesia

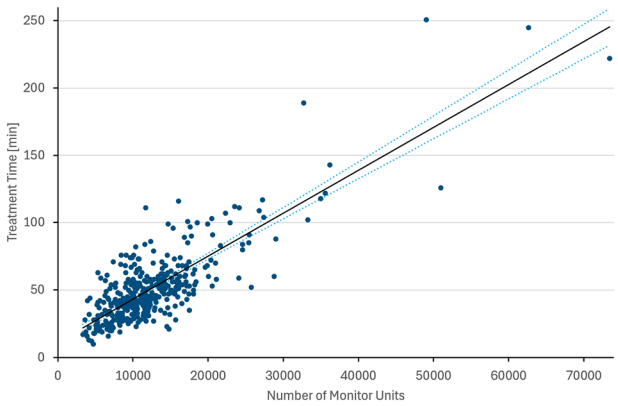

Figure 4. Total treatment time versus monitor units.

6 months after GRS and has improved after proper training. Two patients underwent ventriculoperitoneal shunt implantation due to a nonobstructive hydrocephalus after GRS without tumor enlargement (1.0%). A detailed analysis of hearing outcomes after GRS will be reported separately.

Uveal Melanomas

Of 382 patients enrolled, 17 were suffering from uveal melanomas. Treatment delivery was performed in collaboration with an attending ophthalmologist, who was responsible for determining the clinical indication, administering retrobulbar anesthesia, and providing clinical follow-up. No recurrence was observed during the available imaging follow-up (median: 3.7 months; range: 2.6–8.5 months). Tumor shrinkage was observed in 13 of the tumors treated (76%). The eye-preservation rate was 100%. One patient showed pseudoprogression after GRS, followed by vitrectomy and silicone tamponade, which affected the volumetric assessment. Ophthalmological examination confirmed stable disease. A detailed analysis of visual outcomes after GRS will be reported separately.

Brain Metastases

Overall, of the entire cohort of patients with brain metastases, 19 were diagnosed with lung tumors, one with colorectal cancer, one with ovarian cancer, 15 with breast cancer, 9 with malignant melanoma, 7 with renal cell carcinoma, one with prostate cancer, one with solitary fibrous sarcoma, and one with poorly differentiated thyroid cancer. The median imaging follow-up was 10.5 months (range: 0.6–30.2 months). Seventy-four tumors (39%) show a volume shrinkage after GRS. Two patients developed extensive leptomeningeal disease following SRS. Two patients (3.5%) died due to cerebral tumor progression, and 2 more patients underwent whole-brain radiotherapy (WBRT) due to tumor recurrence and diagnosis of new metastases. Three patients developed notable radiation adverse effects after GRS. Two patients underwent supportive therapy with dexamethasone and bevacizumab, respectively, which resolved the issue. One patient underwent microsurgery due to the enlargement of the tumor volume, which resulted in neurological deterioration and histological confirmation of both radiation necrosis (RN) and tumor recurrence. This patient was then referred for hypofractionated radiation therapy to the resection cavity in an adjuvant setting, and currently shows no signs of local recurrence, having partially recovered. One patient was treated for multiple brain metastases over 5 years with RRS, with one metastasis being treated with GRS. Unfortunately, the patient underwent surgery due to an enlarging and symptomatic RN, which was unrelated to the metastasis that had been treated with GRS. This metastasis remained stable over a 6-month follow-up period.

Pituitary Adenomas

Fourteen of 21 patients had a nonsecretory pituitary adenoma. The median imaging follow-up was 11.1 months (range: 5.5–24.2 months). Overall, 6 of 21 tumors show a volume decrease after GRS (28%). One tumor was invading the sella in two portions, so the volumetric assessment was divided into two lesions. No adverse radiation effects or imaging signs of tumor recurrence

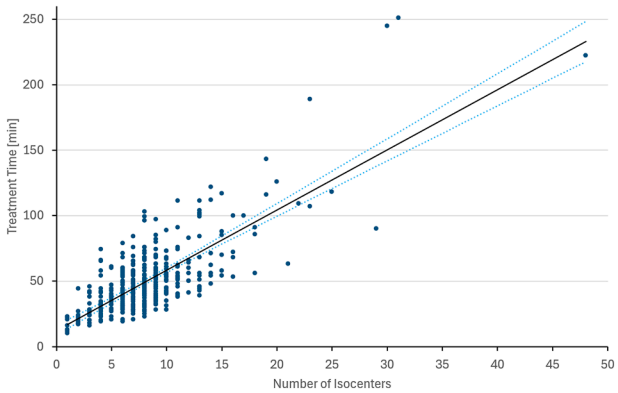

Figure 5. Total treatment time versus number of isocenters.

occurred in the cohort of patients harboring pituitary adenomas. Neither visual impairment nor new or worsening hypopituitarism was observed.

DISCUSSION

This report updates our first analysis about the efficacy and safety of GRS for intracranial lesions. Although retrospective data are available, to our knowledge, this study is the largest prospective analysis of GRS use, encompassing more than 500 tumors.[5,6]

Treatment Plan and Dosimetry Workflow

In our previous report, we outlined some of the difficulties we encountered in a few situations, such as prolonged setup times.[5,9,17] From a technical standpoint, we have recently reported that the update of the GRS planning system and the introduction of a new headrest design have resulted in a notable improvement in the treatment plans for GRS.[9] We reported a significantly better nCI and GI than the previous GRS plans. Nevertheless, the number of beams, MUs, and expected treatment time increase significantly with the new GRS treatment planning system.[9] The new thermoplastic mask and headrest, despite being slightly tighter, were well tolerated by patients. Hofmann et al. analyzed the GRS plan quality, comparing it to plans with the old and new headrests to RRS as an established reference platform. RRS and GRS systems now exhibit comparable plan quality, with a trend

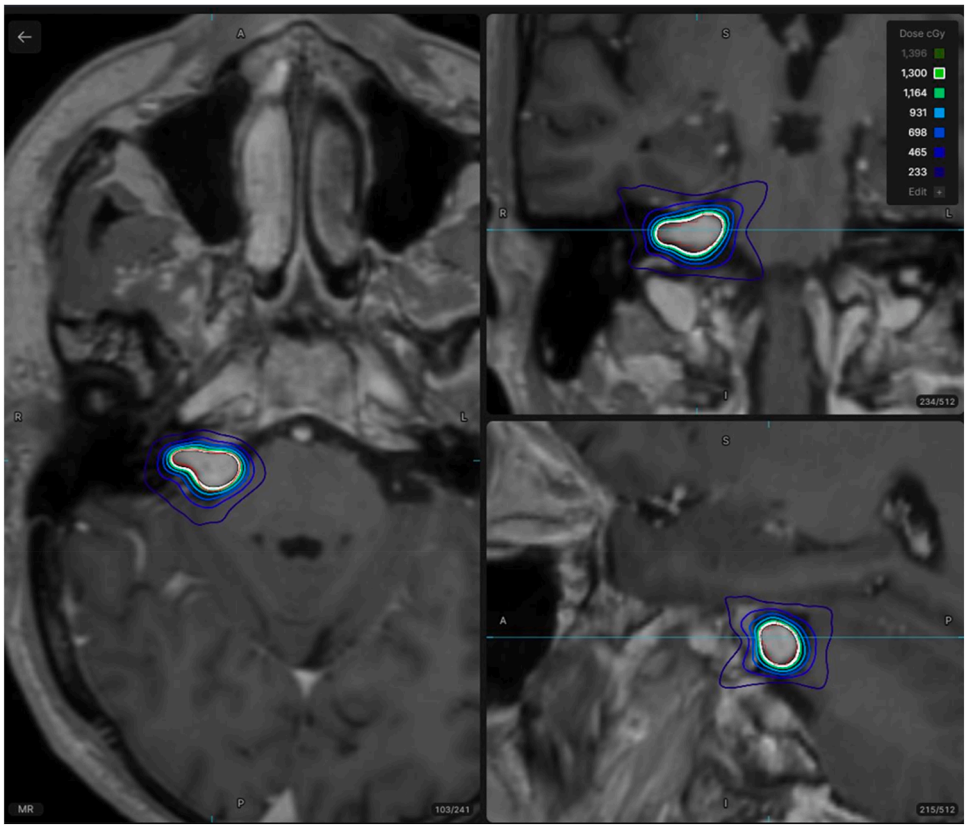

Figure 6. Treatment plan of a vestibular schwannoma treated with 13 Gy, prescribed to the 56% isodose line.

Table 1. Patient and Tumor Characteristics

Number of Patients	382			
Number of Tumors	541			
Gender (Male/Female, %)	40.6/59.4			
	Median	**Mean (SD)**	**IQR**	**Range**
Age (years)	60.2	59.4 (13.0)	52.0—68.0	15.9—88.6
Target volume vestibular schwannoma (cc)	0.7	1.1 (1.1)	0.4—1.5	0.05—5.2
Prescription dose vestibular schwannoma (Gy)	13.0	13.0 (0.1)	13.0—13.0	13.0—13.5
Prescription isodose line vestibular schwannoma (%)	54.0	54.4 (4.9)	54.0—58.0	44.0—67.0
Target volume meningioma (cc)	1.6	2.1 (1.7)	0.7—3.2	0.2—8.5
Prescription dose meningioma (Gy)	15.0	15.1 (1.0)	14.0—15.5	13.0—18.0
Prescription isodose line meningioma (%)	53.0	53.0 (5.2)	50.0—56.0	40.0—70.0
Target volume brain metastases (cc)	0.2	0.7 (1.4)	0.1—0.6	0.02—10.4
Prescription dose brain metastases (Gy)	20.0	20.2 (0.9)	20.0—21.0	18.0—22.0
Prescription isodose line brain metastases (%)	57.0	57.8 (8.3)	52.0—62.0	42.0—82.4
Target volume pituitary adenoma (cc)	1.8	2.2 (2.0)	0.9—2.9	0.2—9.2
Prescription dose pituitary adenoma (Gy)	18.0	18.6 (1.4)	18.0—19.0	16.0—22.0
Prescription isodose line pituitary adenoma (%)	52.0	52.2 (3.6)	50.0—55.0	43.0—57.0
Target volume uveal melanoma (cc)	1.2	1.2 (0.7)	0.8—1.3	0.6—3.5
Prescription dose uveal melanoma (Gy)	21.0	21.0 (0.0)	21.0—21.0	21.0—21.0
Prescription isodose line uveal melanoma (%)	52.0	53.5 (5.6)	49.0—55.0	47.0—67.0

SD, Standard deviation; IQR, interquartile range.

toward sharper gradients in GRS, but lower conformity, attributed to the specialized delivery design. Compared to GRS plans, the nCI of RRS plans is better, but the GI is worse. The total number of beams and MUs was significantly lower with the RRS platform, while the expected treatment times were equivalent.[9]

A comparison of state-of-the-art SRS platforms, including GRS, RRS, GK, Elekta Versa, Varian TrueBeam, and Edge, was performed concerning median target coverage and GI. The results were consistent with our previous report on GRS.[5,6,18] Niu et al. have recently compared the plan quality and delivery efficiency for both GRS and RRS for brain metastases treatment. Twenty three patients harboring a total of 47 brain metastases, were included in the creation of dedicated plans for GRS and RRS. The data show better CI and HI for RRS, while GRS exhibited better GI and a smaller irradiated volume for the normal brain. The superiority of RSS plan conformity was higher for target sizes less than 1 cc and more than 10 cc, while the advantage of GRS's plan dose gradient was more notable for target sizes less than 10 cc.[19] Suzuki et al. analyzed various radiotherapy techniques for treating brain metastases, focusing on noncoplanar volumetric modulated arc radiotherapy, coplanar volumetric modulated arc radiotherapy, helical tomotherapy, RRS, GK, and GRS. Computed tomography images and structures of 12 patients who underwent RRS for a single brain metastasis were used.[20] twelve radiation treatment plans were calculated for each device. noncoplanar volumetric modulated arc radiotherapy and coplanar volumetric modulated arc radiotherapy had shorter treatment times than other techniques in both groups. GRS showed better outcomes in GI and CI for smaller tumors, such as GK, while differences with noncoplanar volumetric modulated arc radiotherapy and RRS diminish increasing tumor volumes.[20] GRS, RRS, and GK have longer treatment times than other treatment techniques regardless of volume. There was no statistical difference in the mean values of GI and CI between GRS and GK ($P > 0.05$).[20]

Clinical Considerations

Intracranial Meningiomas. Imaging-defined and WHO grade 1 meningiomas exhibit a good imaging response to SRS, resulting in more than 90% long-term control. A cohort study of 972 patients with 1045 meningiomas from the University of Pittsburgh reported a 93% control rate in patients with WHO grade 1 meningiomas who received adjuvant SRS, while primary SRS patients without a biopsy-confirmed histologic grading achieved a tumor control rate of 97%.[21] These results were confirmed by further reports on imaging outcomes and treatment safety.[22,23] Previous reports have demonstrated that volumetric assessment confirms shrinkage rates exceeding 40% after SRS.[24] Toxicity and adverse radiation effects were rare, thus showing results in line

Table 2. Treatment Characteristics

	Median	Mean (SD)	IQR	Range
Number of treated lesions per treatment	1	1.3 (1.2)	1—1	1—12
Conformity index	1.19	1.22 (0.12)	1.15—1.25	1.05—2.31
Normal conformity index	1.23	1.25 (0.12)	1.18—1.29	1.09—2.33
Homogeneity index	1.85	1.85 (0.19)	1.72—2.00	1.21—2.50
Gradient index	3.01	3.09 (0.46)	2.76—3.30	2.37—5.41
Coverage (%)	97.4	97.2 (1.7)	96.2—98.4	83.8—100.0
Total treatment time (minutes)	46	51 (28)	35—58	10—251
Setup time (minutes)	9	12 (10)	4—16	1—56
Delivery time (minutes)	31	35 (21)	24—39	7—214
Number of isocenters	8	8.4 (4.6)	6—10	1—48
Monitor units	11,207	12,571 (7377)	8731—14,444	3323—73,410
Number of beams	105	121 (68)	84—141	30—677

SD, Standard deviation; IQR, interquartile range.

with previous contributions.[23,25-28] Little is known about the factors related to pseudoprogression, peritumoral edema, and intratumoral necrosis occurring after SRS. A recent study identified several statistically significant factors related to pseudoprogression, including TV exceeding 3 cc, selectivity exceeding 70%, a GI exceeding 2.70, pretreatment edema, and intratumoral necrosis.[29] The occurrence of clinically relevant edema and swelling happens to be a relatively rare event, as previously described in other series.[23] These findings align with our preliminary results. The efficacy of upfront SRS for meningiomas has decreased the need to expose patients to aggressive microsurgical resection and related morbidity, especially when a gross total resection is not achievable.[30] Indeed, a better imaging outcome was observed for those meningiomas that had not been previously resected compared to those that underwent gross total or subtotal resection. Nevertheless, SRS in a recurrent setting to the residual tumor is also now recommended rather than waiting for signs of imaging tumor growth on active surveillance.[22,23,31]

Table 3. Complications in 29 Patients Treated with Gyroscopic Radiosurgery

Diagnosis	Description	Number of Cases	
Vestibular schwannoma	Vertigo CTCAE*	2 cases grade 3	6 cases grade 2
	Tinnitus CTCAE	3 cases grade 3	
	Facial palsy CTCAE H&B†	2 cases grade 3 grade V	1 case grade 3 grade IV
	Nonobstructive hydrocephalus CTCAE	2 cases grade 3	
Meningioma	Symptomatic edema CTCAE	9 cases grade 3	
Uveal melanoma	Surgery after GRS CTCAE	1 case grade 3	
Brain metastasis	Radiation necrosis CTCAE	3 cases grade 3	

GRS, gyroscopic radiosurgery.
*Common Terminology Criteria for Adverse Events (CTCAE) v 5.0.
†H&B, House-Brackmann score.

Vestibular Schwannomas. The efficacy and safety of SRS for vestibular schwannomas have now been established by many reports.[32-39] Volume shrinkage as well as swelling after SRS is a well-documented effect; however, the reliability of volumetric assessment remains debated due to the different patterns of response that can occur before an enlargement should be considered a recurrence.[40-44] Balossier et al. recently described 5 different patterns of post-SRS swelling in a cohort of 1607 patients treated with GK radiosurgery for vestibular schwannoma.[39] These reports demonstrate the wide variety of swelling responses after SRS, and addressing repeated SRS should be carefully considered, taking into account the variability in imaging evolution patterns of vestibular schwannomas after SRS. Although the follow-up available in our series is very short, the volumetric assessment confirms a dynamic response after GRS. Current treatment paradigms for vestibular schwannoma have clearly turned in favor of SRS, with up to a 41% decrease in rates of surgical resection for these benign tumors.[36,45,46] In a recent meta-analysis of 23 studies involving a comprehensive cohort of 1409 patients with a median follow-up period of 6.7 years, Balossier et al. reported hearing preservation in 59.4% of cases and a facial nerve deficit in 1.3% of cases, with higher rates of

toxicity to the cranial nerves in SRS linac-based versus GK-based treatment.[36] We report 1 case of facial nerve palsy that occurred in a recurrence setting after a previous RRS. Balossier et al. have reported the outcomes of repeat SRS for progressive vestibular schwannoma after previous radiosurgery and described a new facial nerve palsy in 4.3% of patients treated.[33]

Hydrocephalus following SRS for vestibular schwannoma has been widely reported as an unpleasant, although rare, adverse event that leads to ventriculoperitoneal shunting.[47] Such an event is poorly understood because it can be caused by either obstructive, in the case of a large vestibular schwannoma, or malresorptive pathophysiology.[48,49] Recently, Santhumayor et al. evaluated the risk factors associated with the development of nonobstructive hydrocephalus in a cohort of 378 patients undergoing SRS for sporadic vestibular schwannomas, neither operated on nor irradiated. Baseline tumor volume, third ventricle width, and Evans Index, defined as the maximum width of the frontal horns of the lateral ventricles/maximum internal diameter of the skull, were at increased odds of developing post-SRS hydrocephalus.[50]

The advent of more precise stereotactic planning software, which uses high-resolution magnetic resonance imaging and computed tomography imaging, has enabled improved conformal dose planning and the use of more radiation isocenters and smaller beams, resulting in the preservation of critical structures and a significant reduction in treatment-related comorbidities. In SRS for vestibular schwannomas, the cochlea, the vestibular cochlear nerve, the facial nerve, the trigeminal nerve, and the brainstem are considered critical structures.[30] Previous reports have shown that doses exceeding 13 Gy can lead to hearing loss, facial nerve palsy, and trigeminal neuropathy.[51,52]

Uveal Melanomas. Uveal melanomas require close, interdisciplinary collaboration between ophthalmologists and physicians dedicated to radiosurgery, such as neurosurgeons or radiation oncologists. The value of SRS for the management of uveal melanomas has been extensively demonstrated.[17,53,54] Recently, 2 case reports highlighted the feasibility of GRS for uvea melanomas.[7,55] One contribution discussed the feasibility of GRS in comparison to the RRS procedure. The procedure was performed without complications, was reliably performed, and was well tolerated by the patient in an outpatient setting.[7]

Brain Metastases. In our previous study, we have extensively evaluated the volumetric response of brain metastases after GRS.[6] Although in 1 case, an adverse radiation effect after GRS led to a further surgery, no significant morbidity related to the treatment was observed during the limited follow-up. Recently, a growing body of scientific reports has shown that stereotactic treatment of a limited number of brain metastases, compared to WBRT, can preserve cognitive function and quality of life without affecting patients' overall survival.[4,56]

During the pioneering era of radiosurgery, numerous reports outlined the efficacy and safety of this treatment using both linacs and GK devices.[57-59] SRS lessens the subacute and chronic adverse effects of WBRT, such as hair loss and cognitive decline, and has made it the method of choice for treating small-sized to medium-sized brain metastases.[30,60-66] The feasibility of SRS in an outpatient setting makes it a valuable tool for the management of asymptomatic brain metastases.[67] As highlighted in the guidelines from the American Society of Clinical Oncology, the Society for Neuro-Oncology, and the American Society for Radiation Oncology, SRS can be used for metastases measuring up to 3 cm in diameter and fractionated SRS for lesions measuring between 3 and 5 cm in diameter.[4,30,56,68] A variety of factors have been shown to influence the imaging and clinical outcomes of SRS, including, but not limited to, the number of metastases, tumor diameter, tumor histology subtype, tumor location, extracranial disease control, and patient age.[30,69-74]

A recent study by Upadhyay et al. reported 1 of the largest cohorts of patients to receive SRS for 15 or more brain metastases over 8 years. The study concluded that SRS was safe and provided comparable cognitive and survival benefits to those reported in studies using WBRT.[75] The occurrence of RN is well described in the literature and requires careful observation to select the most effective therapeutic strategy based on clinical and imaging follow-up.

Pituitary Adenomas. Nonsecreting pituitary adenomas represent approximately 30% of pituitary tumors.[76] The goals of SRS for nonfunctioning pituitary tumors are to control tumor growth while preserving the pituitary function and the optic pathways.[77] SRS should be reserved for small, well-defined tumors in an adjuvant or recurrence setting.[78] Many reports have confirmed high control rates of more than 90%, with hypopituitarism rates slightly exceeding 20% observed in long-term follow-up.[76,79,80]

Secreting pituitary adenomas tend to respond differently to SRS depending on the hormone they produce. Acromegaly responded best to SRS, with more than 70% experiencing normalized growth hormone secretion.[81] Patients with persistent Cushing's disease who received SRS at a mean marginal dose of 22 Gy achieved 98% tumor control and 70% remission of their Cushing's disease at a mean follow-up of 48 months. 27% of patients diagnosed with prolactinomas experienced resolution of their endocrine dysfunction, and 55% showed improvement in endocrine function after SRS at a median follow-up period of 36 months.[82-85] The current recommendation for SRS treatment of adenomas is a single fraction of 12–20 Gy, with higher doses (16–20 Gy) reserved for functioning/secretory adenomas. The maximum dose to the optic pathways should be kept below 8 Gy.[30,77,86]

Study Limitations

Although the data were collected in a prospective setting, this report is primarily a descriptive analysis of a newly introduced radiosurgery platform, detailing dosimetric and clinical outcomes. An in-depth evaluation of imaging outcomes was not performed, as the median follow-up period of less than a year does not allow for an appropriate analysis.

CONCLUSION

This study provides an update on our experience with the use of GRS in treating intracranial tumors. During the available follow-up, we observed a favorable volumetric tumor response and acceptable toxicity. Indeed, we report a shift in clinical indications and use, with most patients being treated for benign

tumors. Although longer imaging and clinical follow-up are mandatory to assess the treatment's long-term efficacy and safety, the results show the feasibility, efficacy, and acceptable morbidity of GRS as the first dedicated self-shielding platform for cranial radiosurgery.

CRediT AUTHORSHIP CONTRIBUTION STATEMENT

Antonio Santacroce: Writing — review & editing, Writing — original draft, Validation, Supervision, Project administration, Methodology, Investigation, Formal analysis, Data curation, Conceptualization. **Alexander Muacevic:** Writing — review & editing, Validation, Supervision. **Nadja Kohlhase:** Writing — review & editing, Validation. **Dochka Eftimova:** Writing — review & editing, Validation. **Theresa Hofmann:** Writing — review & editing, Validation. **Matthias Sammer:** Writing — review & editing, Validation. **Annabel Graser:** Writing — review & editing, Validation. **Markus Kufeld:** Writing — review & editing, Validation. **Christoph Fürweger:** Writing — review & editing, Supervision, Investigation, Formal analysis, Data curation. **Felix Ehret:** Writing — review & editing, Validation, Supervision, Formal analysis, Conceptualization.

ACKNOWLEDGMENTS

The authors are grateful for the support provided by the Foundation 'Deutsche Stiftung Neurologie'.

REFERENCES

1. Trifiletti DM, Ruiz-Garcia H, Quinones-Hinojosa A, Ramakrishna R, Sheehan JP. The evolution of stereotactic radiosurgery in neurosurgical practice. *J Neurooncol*. 2021;151:451-459.
2. Fatima N, Meola A, Ding VY, et al. The Stanford stereotactic radiosurgery experience on 7000 patients over 2 decades (1999-2018): looking far beyond the scalpel. *J Neurosurg*. 2021;135:1-17.
3. Sheehan JP, Yen CP, Lee CC, Loeffler JS. Cranial stereotactic radiosurgery: current status of the initial paradigm shifter. *J Clin Oncol*. 2014;32:2836-2846.
4. Schiff D, Messersmith H, Brastianos PK, et al. Radiation therapy for brain metastases: ASCO guideline endorsement of ASTRO guideline. *J Clin Oncol*. 2022;40:2271-2276.
5. Muacevic A, Eder MM, Hofmann T, Fürweger C, Ehret F. Self-shielding gyroscopic radiosurgery-a first clinical experience, Case series, and dosimetric comparison. *World Neurosurg*. 2022;164:e420-e426.
6. Ehret F, Kohlhase N, Eftimova D, et al. Self-shielding gyroscopic radiosurgery: a prospective experience and analysis of the first 100 patients. *Cureus*. 2024;16:e56035.
7. Foerster P, Klaas J, Furweger C, Ehret F, Muacevic A, Santacroce A. Self-Shielding gyroscopic radiosurgery for Uveal melanoma: a first case report. *Cureus*. 2024;16:e59859.
8. Hendricks BK, et al. ZAP-X gyroscopic radiosurgery System: a preliminary analysis of clinical applications within a retrospective Case series. *Stereotact Funct Neurosurg*. 2021;100:1-9.
9. Hofmann T, Sammer M, Kohlhase N, et al. Treatment plan comparison between self-shielding gyroscopic radiosurgery and robotic radiosurgery. *Cureus*. 2025;17:e82990.
10. Lee YC, Tolakanahalli R, Wieczorek DJ, et al. Routine machine quality assurance tests for a self-shielded gyroscopic radiosurgery system. *J Appl Clin Med Phys*. 2025;26:e14589.
11. Sallabanda M, Arrojo Álvarez EE, Aguilar B, Ruiz Echevarría AL, Huertas Modéjar H, Sallabanda K. Reirradiation of large or multifocal high-grade gliomas with gyroscopic radiosurgery in combination with modulated electro-hyperthermia. *Cureus*. 2025;17:e83511.
12. Sallabanda M, Sallabanda K. Gyroscopic radiosurgery for the treatment of trigeminal neuralgia. *Cureus*. 2025;17:e81011.
13. Stapper C, Gerlach S, Hofmann T, Fürweger C, Schlaefer A. Automated isocenter optimization approach for treatment planning for gyroscopic radiosurgery. *Med Phys*. 2023;50:5212-5221.
14. Ohtakara K, Hayashi S, Hoshi H. The relation between various conformity indices and the influence of the target coverage difference in prescription isodose surface on these values in intracranial stereotactic radiosurgery. *Br J Radiol*. 2012;85:e223-e228.
15. Nakamura JL, Verhey LJ, Smith V, et al. Dose conformity of gamma knife radiosurgery and risk factors for complications. *Int J Radiat Oncol Biol Phys*. 2001;51:1313-1319.
16. Paddick I, Lippitz B. A simple dose gradient measurement tool to complement the conformity index. *J Neurosurg*. 2006;105:194-201.
17. Ehret F, Fürweger C, Liegl R, et al. Tumor control probability and time-dose-response modeling for stereotactic radiosurgery of Uveal melanoma. *Int J Radiat Oncol Biol Phys*. 2024;120:1052-1057.
18. Paddick I, et al. Benchmarking tests of contemporary SRS platforms: have technological developments resulted in improved treatment plan quality? *Pract Radiat Oncol*. 2023;13:e451-e459.
19. Niu Y, Rashid A, Lee JM, et al. Comparative analysis of plan quality and delivery efficiency: ZAP-X vs. cyberknife for brain metastases treatment. *Front Oncol*. 2024;14:1333642.
20. Suzuki T, Saito M, Nomura R, et al. Stereotactic radiotherapy for metastatic brain tumors: a comparative analysis of dose distributions among VMAT, helical tomotherapy, cyberknife, gamma knife, and ZAP-X. *J Appl Clin Med Phys*. 2025;26:e70046.
21. Kondziolka D, Mathieu D, Lunsford LD, et al. Radiosurgery as definitive management of intracranial meningiomas. *Neurosurgery*. 2008;62:53-58 [discussion: 58-60].
22. Santacroce A. Stereotactic radiosurgery for benign cavernous sinus meningiomas: a multicentre study and review of the literature. *Cancers (Basel)*. 2022;14:4047.
23. Santacroce A, Walier M, Régis J, et al. Long-term tumor control of benign intracranial meningiomas after radiosurgery in a series of 4565 patients. *Neurosurgery*. 2012;70:32-39 [discussion: 39].
24. Feigl GC, Samii M, Horstmann GA. Volumetric follow-up of meningiomas: a quantitative method to evaluate treatment outcome of gamma knife radiosurgery. *Neurosurgery*. 2007;61:281-286 [discussion: 286-7].
25. Pinzi V, Marchetti M, Viola A, et al. Hypofractionated radiosurgery for large or in critical-site intracranial meningioma: results of a phase 2 prospective study. *Int J Radiat Oncol Biol Phys*. 2023;115:153-163.
26. Marchetti M, Sahgal A, De Salles AAF, et al. Stereotactic radiosurgery for intracranial non-cavernous sinus benign meningioma: international stereotactic radiosurgery Society systematic review, meta-analysis and practice guideline. *Neurosurgery*. 2020;87:879-890.
27. Pinzi V, Marchetti M, De Martin E, et al. Multisession radiosurgery for intracranial meningioma treatment: study protocol of a single arm, monocenter, prospective trial. *Radiat Oncol*. 2020;15:26.
28. Pinzi V, Bisogno I, Ciusani E, et al. In vitro assessment of radiobiology of meningioma: a pilot study. *J Neurosci Methods*. 2019;311:288-294.
29. Jung IH, Chang KW, Park SH, et al. Pseudoprogression and peritumoral edema due to intratumoral necrosis after gamma knife radiosurgery for meningioma. *Sci Rep*. 2022;12:13663.
30. Lam FC, Byun J, Guru S, et al. Understanding the radiobiology of central nervous system diseases in the golden age of radiosurgery-does it matter? *Brain Sci*. 2025;15:649.
31. Lee JY, Niranjan A, McInerney J, Kondziolka D, Flickinger JC, Lunsford LD. Stereotactic radiosurgery providing long-term tumor control of cavernous sinus meningiomas. *J Neurosurg*. 2002;97:65-72.

32. Troude L, Boucekine M, Montava M, et al. Does NF2 status impact the results of combined surgery and adjunctive gamma knife surgery for large vestibular schwannomas? *Neurosurg Rev*. 2020;43:1191-1199.

33. Balossier A, Régis J, Reyns N, et al. Repeat stereotactic radiosurgery for progressive vestibular schwannomas after previous radiosurgery: a systematic review and meta-analysis. *Neurosurg Rev*. 2021;44:3177-3188.

34. Troude L, Boucekine M, Balossier A, et al. Is salvage surgery for large vestibular schwannomas after failed gamma knife radiosurgery more challenging? *Neurosurg Rev*. 2022;45:751-761.

35. Balossier A, Delsanti C, Troude L, Thomassin JM, Roche PH, Régis J. Assessing tumor volume for sporadic vestibular schwannomas: a comparison of methods of volumetry. *Stereotact Funct Neurosurg*. 2023;101:265-276.

36. Balossier A, Tuleasca C, Delsanti C, et al. Long-term hearing outcome after radiosurgery for vestibular schwannoma: a systematic review and meta-analysis. *Neurosurgery*. 2023;92:1130-1141.

37. Balossier A, Sahgal A, Kotecha R, et al. Management of sporadic intracanalicular vestibular schwannomas: a critical review and International Stereotactic Radiosurgery Society (ISRS) practice guidelines. *Neuro Oncol*. 2024;26:429-443.

38. Troude L, Ogando YE, Balossier A, Baucher G, Régis J, Roche PH. Surgical management of large lower cranial nerves schwannomas: long term results of a less aggressive resection strategy. *Neurosurg Rev*. 2024;47:171.

39. Balossier A, Olteanu M, Delsanti C, et al. Dynamics of tumor evolution after gamma knife radiosurgery for sporadic vestibular schwannoma: defining volumetric patterns characterizing individual trajectory. *Neuro Oncol*. 2025;27:545-556.

40. Gurewitz J, Schnurman Z, Nakamura A, et al. Hearing loss and volumetric growth rate in untreated vestibular schwannoma. *J Neurosurg*. 2022;136:768-775.

41. Benjamin CG, Schnurman Z, Ashayeri K, et al. Volumetric growth rates of untreated cavernous sinus meningiomas. *J Neurosurg*. 2022;136:749-756.

42. Marinelli JP, Killeen DE, Schnurman Z, et al. Spontaneous volumetric tumor regression during wait-and-scan management of 952 sporadic vestibular schwannomas. *Otol Neurotol*. 2022;43:e1034-e1038.

43. Marinelli JP, Schnurman Z, Killeen DE, et al. Long-term natural history and patterns of sporadic vestibular schwannoma growth: a multi-institutional volumetric analysis of 952 patients. *Neuro Oncol*. 2022;24:1298-1306.

44. Albano L, Deng H, Wei Z, Vodovotz L, Niranjan A, Lunsford LD. The longitudinal volumetric response of vestibular schwannomas after gamma knife radiosurgery. *J Neurosurg*. 2023;138:1273-1280.

45. Patel S, Nuño M, Mukherjee D, et al. Trends in surgical use and associated patient outcomes in the treatment of acoustic neuroma. *World Neurosurg*. 2013;80:142-147.

46. Kano H, Kondziolka D, Khan A, Flickinger JC, Lunsford LD. Predictors of hearing preservation after stereotactic radiosurgery for acoustic neuroma. *J Neurosurg*. 2009;111:863-873.

47. De Sanctis P, Green S, Germano I. Communicating hydrocephalus after radiosurgery for vestibular schwannomas: does technique matter? A systematic review and meta-analysis. *J Neurooncol*. 2019;145:365-373.

48. Pikis S, Mantziaris G, Kormath Anand R, et al. Stereotactic radiosurgery for Koos grade IV vestibular schwannoma: a multi-institutional study. *J Neurosurg*. 2023;138:405-412.

49. Lee SH, Seol HJ, Kong DS, et al. Risk factors and tumor response associated with hydrocephalus after gamma knife radiosurgery for vestibular schwannoma. *Acta Neurochir (Wien)*. 2012;154:1679-1684.

50. Santhumayor BA, Mashiach E, Meng Y, et al. Predictors of hydrocephalus risk after stereotactic radiosurgery for vestibular schwannomas: utility of the Evans index. *Neurosurgery*. 2025;96:650-659.

51. Foote KD, Friedman WA, Buatti JM, Meeks SL, Bova FJ, Kubilis PS. Analysis of risk factors associated with radiosurgery for vestibular schwannoma. *J Neurosurg*. 2001;95:440-449.

52. Kondziolka D, Lunsford LD, McLaughlin MR, Flickinger JC. Long-term outcomes after radiosurgery for acoustic neuromas. *N Engl J Med*. 1998;339:1426-1433.

53. Muacevic A, Nentwich M, Wowra B, Staerk S, Kampik A, Schaller U. Development of a streamlined, non-invasive robotic radiosurgery method for treatment of Uveal melanoma. *Technol Cancer Res Treat*. 2008;7:369-374.

54. Eibl-Lindner K, Fürweger C, Nentwich M, et al. Robotic radiosurgery for the treatment of medium and large Uveal melanoma. *Melanoma Res*. 2016;26:51-57.

55. Kinzl S, Heussen F, Kaiser KP, et al. Treatment of Uveal melanoma using a novel radiosurgical platform: a case report. *Cureus*. 2025;17:e81343.

56. Vogelbaum MA, Brown PD, Messersmith H, et al. Treatment for brain metastases: ASCO-SNO-ASTRO guideline. *J Clin Oncol*. 2022;40:492-516.

57. Sturm V, Kober B, Höver KH, et al. Stereotactic percutaneous single dose irradiation of brain metastases with a linear accelerator. *Int J Radiat Oncol Biol Phys*. 1987;13:279-282.

58. Lindquist C. Gamma knife surgery for recurrent solitary metastasis of a cerebral hypernephroma: case report. *Neurosurgery*. 1989;25:802-804.

59. Loeffler JS, Kooy HM, Wen PY, et al. The treatment of recurrent brain metastases with stereotactic radiosurgery. *J Clin Oncol*. 1990;8:576-582.

60. Andrews DW, Scott CB, Sperduto PW, et al. Whole brain radiation therapy with or without stereotactic radiosurgery boost for patients with one to three brain metastases: phase III results of the RTOG 9508 randomised trial. *Lancet*. 2004;363:1665-1672.

61. Hasegawa T, Kondziolka D, Flickinger JC, Lunsford LD. Stereotactic radiosurgery for brain metastases from gastrointestinal tract cancer. *Surg Neurol*. 2003;60:506-514.

62. Kondziolka D, Martin JJ, Flickinger JC, et al. Long-term survivors after gamma knife radiosurgery for brain metastases. *Cancer*. 2005;104:2784-2791.

63. Chang EL, Wefel JS, Maor MH, et al. A pilot study of neurocognitive function in patients with one to three new brain metastases initially treated with stereotactic radiosurgery alone. *Neurosurgery*. 2007;60:277-283.

64. Kondziolka D, Niranjan A, Flickinger JC, Lunsford LD. Radiosurgery with or without whole-brain radiotherapy for brain metastases: the patients' perspective regarding complications. *Am J Clin Oncol*. 2005;28:173-179.

65. Brown PD, Jaeckle K, Ballman KV, et al. Effect of radiosurgery alone vs radiosurgery with whole brain radiation therapy on cognitive function in patients with 1 to 3 brain metastases: a randomized clinical trial. *JAMA*. 2016;316:401-409.

66. Brown PD, Ballman KV, Cerhan JH, et al. Postoperative stereotactic radiosurgery compared with whole brain radiotherapy for resected metastatic brain disease (NCCTG N107C/CEC3): a multicentre, randomised, controlled, phase 3 trial. *Lancet Oncol*. 2017;18:1049-1060.

67. Kondziolka D, Shin SM, Brunswick A, Kim I, Silverman JS. The biology of radiosurgery and its clinical applications for brain tumors. *Neuro Oncol*. 2015;17:29-44.

68. Gondi V, Bauman G, Bradfield L, et al. Radiation therapy for brain metastases: an ASTRO clinical practice guideline. *Pract Radiat Oncol*. 2022;12:265-282.

69. Chang EL, Hassenbusch SJ, Shiu AS, et al. The role of tumor size in the radiosurgical management of patients with ambiguous brain metastases. *Neurosurgery*. 2003;53:272-280.

70. Chang SD, Main W, Martin DP, Gibbs IC, Heilbrun MP. An analysis of the accuracy of the cyberknife: a robotic frameless stereotactic radiosurgical system. *Neurosurgery*. 2003;52:140-146.

71. Brown PD, Brown CA, Pollock BE, Gorman DA, Foote RL. Stereotactic radiosurgery for patients with "radioresistant" brain metastases. *Neurosurgery*. 2008;62(Suppl 2):790-801.

72. Lwu S, Goetz P, Monsalves E, et al. Stereotactic radiosurgery for the treatment of melanoma and renal cell carcinoma brain metastases. *Oncol Rep*. 2013;29:407-412.

73. Khan M, Arooj S, Li R, et al. Tumor primary site and histology subtypes role in radiotherapeutic management of brain metastases. *Front Oncol*. 2020;10:781.

74. Ene CI, Abi Faraj C, Beckham TH, et al. Response of treatment-naive brain metastases to stereotactic radiosurgery. *Nat Commun*. 2024;15:3728.

75. Upadhyay R, Palmer JD, Klamer BG, et al. Safety and feasibility of stereotactic radiosurgery for patients with 15 or more brain metastases. *Adv Radiat Oncol*. 2024;9:101509.

76. Sheehan JP, Starke RM, Mathieu D, et al. Gamma knife radiosurgery for the management of nonfunctioning pituitary adenomas: a multicenter study. *J Neurosurg*. 2013;119:446-456.

77. Sheehan JP, Pouratian N, Steiner L, Laws ER, Vance ML. Gamma knife surgery for pituitary adenomas: factors related to radiological and endocrine outcomes. *J Neurosurg*. 2011;114:303-309.

78. Gupta T, Chatterjee A. Modern radiation therapy for pituitary adenoma: review of techniques and outcomes. *Neurol India*. 2020;68:S113-S122.

79. Kotecha R, Sahgal A, Rubens M, et al. Stereotactic radiosurgery for non-functioning pituitary adenomas: meta-analysis and international stereotactic radiosurgery society practice opinion. *Neuro Oncol*. 2020;22:318-332.

80. Mingione V, Yen CP, Vance ML, et al. Gamma surgery in the treatment of nonsecretory pituitary Macroadenoma. *J Neurosurg*. 2006;104:876-883.

81. Kondziolka D, Nathoo N, Flickinger JC, Niranjan A, Maitz AH, Lunsford LD. Long-term results after radiosurgery for benign intracranial tumors. *Neurosurgery*. 2003;53:815-821 [discussion: 821-2].

82. Xu Z, Lee Vance M, Schlesinger D, Sheehan JP. Hypopituitarism after stereotactic radiosurgery for pituitary adenomas. *Neurosurgery*. 2013;72:630-637.

83. Mehta GU, Sheehan JP, Vance ML. Effect of stereotactic radiosurgery before bilateral Adrenalectomy for Cushing's disease on the incidence of Nelson's syndrome. *J Neurosurg*. 2013;119:1493-1497.

84. Sheehan JP, Xu Z, Salvetti DJ, Schmitt PJ, Vance ML. Results of gamma knife surgery for Cushing's disease. *J Neurosurg*. 2013;119:1486-1492.

85. Mathieu D, Kotecha R, Sahgal A, et al. Stereotactic radiosurgery for secretory pituitary adenomas: systematic review and international stereotactic radiosurgery society practice recommendations. *J Neurosurg*. 2022;136:801-812.

86. Pollock BE, Cochran J, Natt N, et al. Gamma knife radiosurgery for patients with nonfunctioning pituitary adenomas: results from a 15-year experience. *Int J Radiat Oncol Biol Phys*. 2008;70:1325-1329.

Conflict of interest statement: The article publishing charge for this manuscript was provided by ZAP Surgical Systems Inc. Antonio Santacroce declares travel support from ZAP Surgical Systems, Inc. Felix Ehret declares a grant from German Cancer Aid. Theresa Hofmann, Felix Ehret, Alexander Muacevic, and Christoph Fürweger declare speaker fees and travel support from ZAP Surgical Systems, Inc. Felix Ehret, Theresa Hofmann, Alexander Muacevic, and Christoph Fürweger declare speaker fees and travel support from Accuray, Inc. All authors declare that there are no other relationships or activities that could appear to have influenced the submitted work.

Received 31 July 2025; accepted 24 November 2025

Citation: World Neurosurg. (2026) 205:124684.
http://doi.org/10.1016/j.wneu.2025.124684

Journal homepage: ***www.journals.elsevier.com/world-neurosurgery***

Available online: ***www.sciencedirect.com***

1878-8750/© 2025 The Author(s). Published by Elsevier Inc. This is an open access article under the CC BY license (http://creativecommons.org/licenses/by/4.0/).