Neuro-Oncology

28(11), 2563–2579, 2026 | https://doi.org/10.1093/neuonc/noag153 | Advance Access publication July 9, 2026

The European Association of Neuro-Oncology consensus statement on radiation necrosis

Johnny Duerinck, Martin Van Den Bent, Petter Brandal, Giuseppe Minniti, Norbert Galldiks, Enrico Franceschi, Marjolein Geurts, Anna S. Berghoff, Mirjam Renovanz, Dieta Brandsma, Tom J. Snijders, Michael Weller, Susan C. Short, Michael Platten, Emilie Le Rhun, Matthias Preusser, Leonille Schweizer, Nathalie Lisa Albert, Julia Furtner, and Evangelia Razis

All author affiliations are listed at the end of the article

Corresponding Authors: Johnny Duerinck, MD PhD, Neurosurgery Department, Universitair Ziekenhuis Brussel, Laarbeeklaan 101, Brussels 1090, Belgium (johnny.duerinck@uzbrussel.be); Evangelia Razis, MD PhD, 3rd Oncology Department, Hygeia Hospital, 4 Erythrou Stavrou Street & Kifisias Avenue, Marousi, Athens 15123, Greece (erazis@oncologists.gr).

Abstract

Background. Radiation necrosis (RN) complicates neuro-oncological care, mimicking tumor recurrence and lacking high-level evidence for standardized management.

Methods. A European Association of Neuro-Oncology (EANO) expert panel utilized a 3-round Delphi process to create a comprehensive expert opinion document based on the available current scientific evidence. A series of statements, derived from the published literature were created by the experts in each field. Consensus was defined as ≥80% agreement using a 5-point Likert scale.

Results. After 3 rounds among 20 experts that included adaptation of statements, the Delphi process reached a consensus (≥80% agreement) on 53 statements out of 57. RN occurs in 4%-30% of patients, typically appearing 6-24 months after radiotherapy for primary (glial) or metastatic brain tumors. Experts identified perfusion MRI and amino acid PET as the most suitable imaging modalities for differentiation from tumor recurrence. While histopathology remains the gold standard, identifying viable tumor cells in irradiated gliomas is challenging due to overlapping cytological features with reactive glia. For symptomatic management, corticosteroids may be tried, and bevacizumab is recommended for corticosteroid-refractory cases, with evidence suggesting profound efficacy even at low doses. Surgery is considered effective for rapid symptom relief and definitive diagnosis in accessible lesions. Laser Interstitial Thermal Therapy (LITT) can be considered an additional treatment option for symptomatic RN.

Conclusions. Despite the absence of Level 1 evidence, these Delphi-survey-formulated recommendations provide actionable guidance for clinical practice. There is a need for prospective randomized trials focusing on symptomatic RN.

Key Points

- Up to 30% of patients with brain tumors treated with radiotherapy develop radiation necrosis, typically presenting 6-24 months after radiotherapy.
- Advanced MRI and amino acid PET enhance diagnostic accuracy, but histopathology remains the gold standard of diagnosis.
- Management of symptomatic RN involves an individualized approach incorporating steroids, bevacizumab or surgery, with preference for surgical resection when feasible.

Received May 5, 2026; accepted July 6, 2026.

© The Author(s) 2026. Published by Oxford University Press on behalf of the Society for Neuro-Oncology. All rights reserved. For commercial re-use, please contact reprints@oup.com for reprints and translation rights for reprints. All other permissions can be obtained through our RightsLink service via the Permissions link on the article page on our site—for further information please contact journals.permissions@oup.com.

Downloaded from academic.oup.com/neuro-oncology/article/28/11/2563/8729059 by DFKZ Zentralbibliothek user on 17 November 2026

Importance of the Study

Radiation necrosis (RN) is a common and potentially debilitating phenomenon in neuro-oncology that complicates patient management significantly. Its clinical importance lies in its associated morbidity and its ability to mimic tumor recurrence, which could lead to either inappropriate treatment escalation or a delay in salvage therapy. Despite its prevalence—occurring in 4%-30% of patients treated with focal radiotherapy—there is a lack of high-level evidence and standardized international guidelines regarding its diagnosis and management.

A Delphi-based consensus process involving a multidisciplinary panel of 20 international experts was used to address this. By establishing high-concordance recommendations (at least 80% agreement) for advanced imaging protocols—specifically the integration of perfusion MRI and amino acid PET—and therapeutic algorithms for corticosteroids and bevacizumab, this consensus statement provides actionable guidance for clinicians. Furthermore, it highlights the need for prospective clinical trials to improve the level of evidence in this complex field.

Radiation necrosis (RN) presents a significant challenge in neuro-oncology. RN poses a particular issue not only because of the symptoms it can cause but also because it can mimic tumor recurrence on conventional imaging. This introduces a diagnostic challenge that could not only lead to inappropriate anti-tumor treatment escalation including re-irradiation, but also, in case of underdiagnosis of recurrence, delayed salvage therapy. Management of RN involves an array of potential treatment options, including corticosteroids, bevacizumab, surgical resection or laser interstitial thermal therapy (LITT), making therapeutic decisions often complex and requiring multidisciplinary expertise.[1,2] The diagnostic and therapeutic challenges posed by RN illustrate the need for the development of international consensus recommendations.

The literature on RN is characterized by low level of evidence, comprising of numerous small, retrospective studies marked by high heterogeneity and inconsistencies, which preclude the construction of robust recommendations through traditional systematic review methods. Therefore, a structured Delphi consensus process was chosen as the most appropriate method for developing formal recommendations on diagnosis and treatment of RN.[3] For this purpose, a panel was composed of experts across essential domains, including radiation oncology, neurology, medical oncology, neurosurgery, neuropathology, radiology and nuclear medicine. Based on an initial literature review, preliminary statements on RN incidence, diagnosis, and treatment were defined and evaluated through an iterative Delphi process. Items were modified or excluded based on panel feedback, resulting in a final set of consensus statements, defined by an agreement rate of at least 80%.

Methods

Expert Panel

A group of 15 experts had volunteered to develop an expert opinion on the management of cerebral RN. The group consisted of 2 radiation oncologists/clinical oncologists, 4 neuro-oncologists, 4 medical oncologists, 2 neurosurgeons, 1 neuropathologist, 1 neuroradiologist and 1 nuclear medicine physician. In the first iteration we also invited 5 more experts to vote: 4 neuro-oncologists and 1 radiation oncologist/clinical oncologist.

Statement Formulation and Voting

Initially, 57 statements were formulated by the experts in their respective field after literature review (Table S1). The statements were separated in categories by topic: Epidemiology-pathophysiology (n = 8)/Causes (n = 10)/Imaging (n = 10)/Histopathology (n = 9)/Management (n = 20)/Research field. The latter was an exploratory set of 8 questions, and the panel was asked to set them in order of priority but as there was no consensus at all in round 1, this section was dropped in round 2 and will only be described briefly at the end.

Subsequently, the first survey round was undertaken, where the panel voted electronically on a 5 (+1) Likert scale (strongly agree-agree-neutral-disagree-strongly disagree and "do not know enough on the topic"). Agreement was defined as the percentage of participants agreeing with the statement (strongly agree and agree combined) of 80% or higher. This excluded participants that claimed to not know enough on the topic to make a statement. If at least 50% of the participants were unable to express their opinion then that specific statement was dropped. After the first round, 15 statements had less than 80% agreement and 6 less than 50%. Then, the points of disagreement were discussed among the group, after which the statements were rephrased and a second round of electronic voting took place. After this round, 4 statements were met with lower agreement (58.8%, 77%, 71%, and 75%, respectively) while the other ones reached more than 80% agreement. The 4 statements were discussed among the group, 1 was dropped and the other ones were accepted after rewording and literature review. Ultimately, this produced a list of 53 accepted statements (Table 1).

Data Collection

Responses for each of the rounds of the Delphi survey were collected using Google forms (Google LLC, Mountain View, CA, USA). Descriptive statistics were used for all 5-point

Downloaded from academic.oup.com/neuro-oncology/article/28/11/2563/8729059 by DFKZ Zentralbibliothek user on 17 November 2026

Downloaded from academic.oup.com/neuro-oncology/article/28/11/2563/8729059 by DFKZ Zentralbibliothek user on 17 November 2026

Table 1. Consensus statements on definition and causes of radiation necrosis

Statement	Accepted in round *n*°	% agreement
Definition and pathophysiology		
Radiation necrosis is an entity that is defined by a combination of clinical, radiological and histopathological features, each of which are non-specific when considered separately	2	86.7%
The pathophysiology of RN involves injury to the tumor microenvironment. Both vascular injury and glial injury are involved in this complex, multifactorial process	2	100.0%
A wide range of incidence rates of RN is reported in the literature, because of the difficulty in setting an unequivocal diagnosis of RN	1	94.4%
Radiation necrosis occurs at a rate of 4%-30% although less than 10% of cases present with symptoms	1	83.3%
There is little evidence showing that the risk of radionecrosis may change significantly for targets located in different brain sites	2	92.0%
Causes		
Radionecrosis most often occurs within 24 months from radiotherapy, however, might also appear several years later	1	88.9%
Although there is no radiotherapy dose in which radionecrosis cannot occur, radionecrosis is unlikely if EQD2 (equivalent dose in 2 Gy fractions) is below 30 Gy	1	81.3%
Fractionation of radiotherapy reduces the risk of radionecrosis	1	88.2%
If the volume of brain (subtracting GTV) that receives 12 Gy (V12Gy) in 1 radiotherapy session is higher than 10 ccm, the risk of radionecrosis increases and a hypofractionated regimen should be considered	1	100.0%
For fractionated radiotherapy of the brain high total dose, high fraction dose and large irradiated volumes are the main risk factors of radionecrosis	1	94.1%
There are no unequivocal patient risk factors such as age, gender or comorbidity that predispose to radionecrosis	1	88.2%
It is currently unknown whether radionecrosis is more frequent following fractionated proton therapy when compared to fractionated photon therapy	3	100.0%
Re-irradiation increases risk of radionecrosis	1	100.0%
Systemic therapy (some agents more than others) before, during or after radiotherapy increases the risk of radionecrosis in brain metastases	1	94.4%
RN risk increases when SRS is given concurrently with WBRT	1	83.3%

Likert-scale items, including absolute and relative frequencies, median, mean, range, and interquartile range (IQR). Agreement thresholds were defined as described above.

Results

Based on the iterative Delphi process and subsequent expert discussions, a final consensus was reached on 53 clinical and research statements. These statements were synthesized into thematic sections to provide a comprehensive framework for clinical practice. The following results detail the panel's consensus, beginning with the definition of cerebral RN and the current understanding of its pathophysiology.

Definition and Pathophysiology

Consensus statements on definition and histopathology are listed in Table 1. Historically, radiotherapy to the CNS was associated with different patterns of adverse events. These were often categorized as (1) acute encephalopathy, (2) early delayed encephalopathy (headache and somnolence syndrome), (3) focal cerebral RN, and (4) diffuse leukoencephalopathy. The observations made in more recent years with standard post-radiotherapy radiological monitoring of an early and transient increase in enhancement, usually within the first months after radiotherapy and mimicking tumor progression, led to the introduction of the term 'pseudo-progression'.[4] This is often a radiological phenomenon but can be accompanied by clinical signs and symptoms.

In contrast, RN refers to a well described histopathological entity with features including extensive coagulative necrosis without pseudopalisading, perivascular fibrosis, vascular hyalinization, reactive vascular changes, dystrophic calcification, perivascular chronic inflammation, and reactive atypia.[5] Patients may be asymptomatic or symptomatic, and the radiological distinction between tumor recurrence and RN is notoriously difficult. Moreover, tumor recurrence and RN often co-exist (including the so-called 'mixed lesions'), which further complicates diagnosis and management.[6] The panel consensus regarding definition is that RN is an entity that is defined by a combination of clinical, radiological and histopathological features, each of which are non-specific when considered separately (Table 1).

Another rarer entity that sometimes develops after stereotactic radiotherapy (SRT) is the very late development over time of enlarging cysts that often require surgery. Here, pathogenetic mechanisms are probably not related to RN.[7] The pathogenetic mechanisms of RN are still only partially

clarified, with the available knowledge mainly derived from animal studies with some studies on human surgical specimens. RN is a late complication of brain radiation, usually occurring between 6 and 24 months after the completion of radiotherapy. It is considered to represent a specific chronic inflammatory response, with an almost historic debate whether the initial damage is to endothelial cells or to glial cells. More recent studies suggest that the progression of RN is a dynamic and continuous process involving complex interactions between various cell populations and altered expression of many growth factors and genes.[2,8] Vascular changes caused by late endothelial injury and apoptosis result in hypoxia with an increased expression of Hypoxia-Inducible Factor-1α (HIF1α) and vascular endothelial growth factor (VEGF) by reactive astrocytes in the peri-necrotic area leading to a breakdown of the blood brain barrier.[8,9]These changes are likely a major cause of both the angiogenesis and subsequent perilesional edema found in RN of the brain.[10] Similarly, Platelet-derived Growth Factor Receptor (PDGFR) and its ligands are overexpressed at the boundary of RN compared to undamaged brain.[11] Inflammatory cytokines also play a role in the pathophysiological mechanism. Radiotherapy results in glial activation leading to the expression of pro-inflammatory cytokines and adhesion molecules, with ICAM-1 protein primarily expressed in endothelial cells and microglia and resulting in induction of TNF-α, IL-1β and ICAM-1 mRNA in microglial cells.

Ionizing radiation was found to activate primary astrocyte cultures without inducing ICAM-1 expression but exposure of astrocytes to conditioned medium collected from irradiated microglia resulted in ICAM-1 induction which could be abrogated by incubation with neutralizing antibodies to TNF-α and IL-1β.[12] COX-2 is significantly induced in astrocyte and microglial cultures by radiation injury, with decreased levels of prostaglandin E and the induction of many inflammatory mediators including TNF-α, IL-1β, IL-6, iNOS, ICAM-1, and MMP-9.[13] Cranial irradiation in the C57BL/6 mouse model resulted in dose-dependent, acute increases in mRNA levels of multiple proinflammatory mediators and markers of activation (TNF-α, ICAM-1) likely contributing to neutrophil infiltration.[14] This response was followed by a delayed infiltration of T-cells and MHC II-positive dendritic cells that persisted for months, indicating that cranial irradiation leads to chronic neuroinflammatory changes.

All these processes appear to contribute to RN but may also represent physiological attempts to repair irradiation-induced tissue damage. As an example, in TNFRp75 knock-out mice, radiation-induced TNF-α, acting through TNFRp75, was shown to protect from the development of late complications of brain irradiation.[15] This suggests that in some patients the radiation repair process is out of control and becomes harmful.

The aforementioned overlap of different post-radiation phenomena and tumor progression often does not permit a clear diagnosis. Thus, the reported incidence rates vary greatly between 4 and 30%, with most reporting symptomatic RN rates of up to 10%.[16-18] Some reports have identified different brain areas such as the subventricular zone and the temporal and occipital lobes as being at increased risk for RN, but the evidence is contradictory.[19]

Causes: Radiotherapy

RN usually occurs between 6 and 24 months after radiation treatment although delayed cases occurring several years after treatment have been consistently reported.[20] Clinically, RN can range from asymptomatic lesions seen as radiological changes on MRI and/or PET to symptomatic patterns of severe neurologic deterioration, including seizures, focal neurological deficits, cognitive impairment, and signs of increased intracranial pressure.[21,22] Available clinical and radiobiological data suggest that RN is uncommon when the equivalent dose in 2 Gy fractions (EQD2), calculated using an α/β ratio of 2 Gy for normal brain tissue, remains below approximately 40 Gy. Above this dose range, the risk of RN increases progressively and is strongly influenced by dose per fraction, total dose, and irradiated brain volume.[19,23] In a pooled analysis of 51 studies on single session and fractionated stereotactic radiotherapy (SRT) for brain metastases published between 1995 and 2018, conducted to identify dosimetric and clinical predictors of radiation-induced brain toxicity, the volume of normal brain (subtracting GTV and non-brain tissue) receiving 12 Gy in a single fraction (V12Gy) was confirmed as 1 of the most robust predictors of RN after single session SRS.[23] A V12Gy of approximately 10 cm^3 was associated with a 5%-10% risk of symptomatic brain necrosis. Fractionated stereotactic radiotherapy may reduce the risk of symptomatic radiation necrosis in selected cases, particularly for larger lesions or lesions located near eloquent brain structures. However, this strategy requires more treatment sessions.[23-25] Such a strategy, however, requires more treatment sessions and several prospective randomized trials are ongoing comparing single session SRS and hypofractionated SRT (SRT, NCT03697343, NCT05222620, NCT05102747 and NCT06500455). In the setting of brain metastases treated with hypofractionated SRT, dose-volume constraints such as a combined brain-plus-target volume V20Gy (3 fractions) or V24Gy (5 fractions) <20 cm^3 have been associated with a <10% risk of any necrosis or edema and a <4% risk of RN requiring surgical resection.[23]

For selected intracranial indications, fractionated proton therapy is increasingly employed to reduce integral dose to normal brain tissue through the physical properties of the Bragg peak.[26] In spite of the favorable physical properties, other characteristics including end-of-range uncertainties, have hindered implementation of intracranial proton SRS.[27] Sensitivity to anatomical and setup changes, and potentially poorer conformality compared with highly conformal photon SRS techniques in selected small intracranial targets should also be considered. To date, no prospective clinical data have demonstrated a clinically meaningful difference in RN incidence compared with photon therapy.[26,28] Similarly, there are no unequivocal patient-related risk factors, such as age, sex, or baseline comorbidities, that consistently predispose to RN.

Downloaded from academic.oup.com/neuro-oncology/article/28/11/2563/8729059 by DFKZ Zentralbibliothek user on 17 November 2026

Downloaded from academic.oup.com/neuro-oncology/article/28/11/2563/8729059 by DFKZ Zentralbibliothek user on 17 November 2026

Re-irradiation of the brain significantly increases the risk of RN in patients undergoing repeat SRS or stereotactic radiotherapy (SRT) for locally recurrent brain tumors.[29] Evidence from re-irradiation series in recurrent glioblastoma indicates that both re-irradiation dose and treated volume must be considered when evaluating RN risk. In this setting, the risk of RN generally remains below 10% for cumulative EQD2 values of approximately 100-110 Gy but may increase to up to 25% when cumulative EQD2 exceeds 130 Gy. Consistently, symptomatic RN rates of approximately 7%-16% have been reported in several published series of repeat SRS for brain metastases performed after either prior SRS or whole-brain radiotherapy (WBRT), with a higher risk observed for lesions with a mean diameter larger than 2.0-3.0 cm.[29]

The combination of RT and systemic treatments is generally feasible without the need for substantial treatment modifications.[30,31] Nevertheless, careful clinical and radiological monitoring is warranted due to the potential increased risk of RN when SRS is combined with dual immune-checkpoint inhibition (CTLA-4 and PD-1 receptor inhibition) or with antibody-drug conjugates in patients with brain metastases.[30-34] Patients with glioma and brain metastases both develop RN, and there is no clear data showing that there is a difference in timing or frequency of occurrence. Current comparative series are limited and largely descriptive. While radiation geometry and underlying tumor location lead to different typical RN distributions (frontotemporal/periventricular in glioma vs more diffuse in metastases), there is no strong evidence that intrinsic RN biology differs between glioma and metastasis patients beyond differences in dose, fractionation, and reirradiation patterns.[22,35,36]

Overall, RN risk reflects a complex interaction between cumulative biologically effective dose and fractionation, treated volume, re-irradiation exposure, and systemic treatment combinations. Individual patient-related predictors remain poorly defined.

Diagnosis

Clinical symptoms.—Distinguishing RN from tumor progression based on clinical symptoms and signs is impossible. In both entities new or worsening focal neurological deficits, seizures, cognitive decline, or symptoms related to increased intracranial pressure (ie, headache, nausea) can occur, whereas both conditions can also be asymptomatic.

Despite the relevance of distinguishing between these 2 conditions, there are no robust clinical studies that directly compare RN with tumor progression in a systematic manner. Most available data originate from retrospective series, mixed cohorts, or imaging-focused studies in which clinical symptoms are recorded descriptively but not analyzed comparatively. As a result, the relative frequency, severity, or temporal pattern of specific symptoms and signs across RN and tumor progression remains insufficiently characterized.[37] Moreover, the absence of standardized symptom reporting frameworks limits interpretation.

In clinical practice, clinical response to corticosteroids or anti-VEGF therapy is sometimes seen as more indicative of RN, yet this lacks good evidence.[38] RN may present with waxing-and-waning deficits or even spontaneous resolution of neurological symptoms, particularly when shifts in vasogenic edema occur. Such transient or spontaneously resolving symptoms are more suggestive of RN and are atypical for true tumor progression, which usually shows a more steadily progressive neurological deterioration.[39] Only new or worsening focal neurological deficits, cognitive decline, headache and/or nausea or epilepsy that can be attributed to RN lesions, should prompt initiation of treatment with corticosteroids or anti-VEGF therapy.[37]

Imaging using advanced MRI and PET.—Consensus statements on imaging of RN are listed in Table 2.

Radionecrosis is a prolonged process that typically appears on neuroimaging between 6 and 24 months after radiotherapy completion.[2] Once developed, the lesion enters a lengthy plateau phase where it can remain stable, fluctuate, or even expand for 12-24 months on conventional MRI.[40,41] Consequently, it often takes many months to several years before any genuine signs of radiological regression or resolution are observed.

Following treatment, both an increase in size of the contrast-enhancing lesion and the signal hyperintensity on FLAIR or T2-weighted MRI sequences are typically used as an indicator of tumor relapse.[42,43] Nevertheless, these findings are nonspecific and may be related to perifocal edema, RN, demyelination, inflammation, or ischemia.[44] Many terms are being used to describe these treatment-related changes on imaging. These include RN, treatment-related changes, etc. A consensus paper by ESTRO proposed the term TRIA (Treatment-Related Imaging Abnormality) as the preferred standard terminology (article in press).

Due to the lack of specificity, the diagnostic performance of structural imaging alone—particularly T1-weighted contrast-enhanced MR sequences—to differentiate tumor progression from RN is limited, with reported sensitivities and specificities of 68% and 77% in WHO grade 3 or 4 gliomas[45] and 79% and 76% in brain metastases, respectively.[46] Given the substantial improvement in diagnostic accuracy with advanced MR sequences when evaluating a new contrast-enhancing lesion suspicious for tumor recurrence or RN, it is recommended to incorporate MR perfusion and/or MR spectroscopy whenever feasible. These advanced MRI techniques provide valuable information on lesional vascularization and metabolism, thereby improving tissue characterization and supporting clinical decision-making.[47] MRI perfusion can be obtained using dynamic susceptibility contrast (DSC), dynamic contrast-enhanced (DCE), or arterial spin labeling (ASL) techniques. Among these, DSC is the most widely available method in clinical practice and has therefore undergone the most extensive validation. While DSC and DCE rely on exogenous contrast agents, ASL offers a fully non-invasive alternative by using magnetically labeled arterial blood water as an endogenous tracer. DSC perfusion measures first-pass T2* signal changes on gradient-recalled echo images following the intravenous application of gadolinium-based contrast agent. Key derived parameters include relative cerebral blood flow (rCBF) and cerebral blood volume (rCBV) and reflect microvascular volume and density that are typically increased in viable brain

Table 2. Consensus statements on imaging and pathology of radiation necrosis

Statement	Accepted in round *n*°	% agreement
Imaging: MRI		
T1-weighted contrast-enhanced sequences alone have low sensitivity and specificity in distinguishing between tumor recurrence and radionecrosis	1	100.0%
The most commonly available advanced MR sequences in routine clinical practice for differentiating between tumor recurrence and radiation necrosis are MR perfusion and MR spectroscopy	1	88.2%
Hyperperfusion and an elevated Choline-Peak are highly indicative of tumor recurrence, whereas low or moderate perfusion and an increased lactate peak suggest radionecrosis	1	100.0%
In follow-up MRI examinations, advanced MR sequences (such as MR-perfusion and/or MR spectroscopy) should be added if a new contrast-enhancing lesion appears suspicious for tumor recurrence or radiation necrosis	2	93.0%
Advanced MRI sequences in combination with amino-acid PET imaging have the highest sensitivity and specificity for differentiating between radiation necrosis and tumor recurrence	1	94.4%
Imaging: PET		
FET, F-DOPA or MET can be used for the differentiation between RN and tumor relapse	1	100.0%
RN shows typically low or no uptake on amino acid PET	1	88.9%
TBRmean is probably better than TBRmax to differentiate between RN and recurrence	3	100.0%
The performance of PET to differentiate between RN and tumor recurrence is reported to be between 80% and 90%	1	94.4%
Serial amino acid PET may be more accurate than single time-point PET to differentiate RN from BM recurrence	1	87.5%
Pathology		
The histopathological examination represents the gold standard for differentiating between radiation necrosis and tumor recurrence in unclear cases	1	83.3%
There is currently no standardized reporting format / accepted protocol for documentation of radiation necrosis in neuropathological specimens	1	100.0%
The accurate identification of neoplastic cells in irradiated gliomas remains a significant diagnostic challenge due to the cytological similarities between tumor cells and reactive glial cells, particularly in the absence of unequivocal malignant features or tumor-specific markers	1	100.0%
In brain metastasis, immunohistochemical lineage markers significantly enhance the detection and quantification of viable tumor cells in most cases, enabling the identification of even single residual tumor cells within necrotic tissue	2	100.0%
In IDH-mutant and diffuse midline gliomas, mutation-specific antibodies (eg, IDH1 R132H and H3 K27M) are useful in distinguishing viable tumor cells from treatment-related changes in post-therapy specimens	1	87.5%
The diagnostic accuracy of intraoperative diagnostic techniques (eg, frozen sections and cytologic preparations) in differentiating between progressive glioma and radiation necrosis remains uncertain	1	86.7%
Due to artifacts introduced during the process of freezing tissue, it is recommended to reserve a portion of the tissue sample for permanent sections without freezing	1	92.9%
The clinical utility of liquid biopsies for distinguishing radiation necrosis from tumor progression in brain cancer patients remains uncertain and requires further investigation	1	100.0%
The prognostic and predictive significance of quantifying viable tumor cells, reactive changes, and necrosis as percentages remains uncertain	1	100.0%

tumor issue while not in areas with therapy-induced changes.[48,49]

High diagnostic accuracy has been demonstrated in grade 3 and 4 gliomas for DSC-derived rCBV in distinguishing viable tumor from post-treatment effects, with pooled sensitivities of 87%-90% and specificities of 86%-88%, underscoring its clinical value.[45,50] In brain metastases, the performance is slightly lower, with pooled sensitivities of 83% and specificities of 78% across 418 lesions in 12 studies.[46]

Proton MR spectroscopy (^{1}H-MRS) supports the differentiation between tumor recurrence and RN by assessing metabolic and chemical tissue characteristics. RN typically exhibits elevated lipid and lactate resonances, whereas recurrent tumors are marked by elevated choline-to-creatine and choline-to-N-acetylaspartate ratios.[45,51] A meta-analysis of 455 patients with glioma reported pooled sensitivities and specificities of 88% and 86% for the Cho/NAA ratio and 83% and 83% for the Cho/Cr ratio.[51] In patients with WHO grade 3 or 4 gliomas in particular (n = 203 patients), performance improved further, with pooled sensitivities and specificities of 91% and 95%.[45] In brain metastases, a meta-analysis of 4 studies comprising 54 lesions showed pooled sensitivity and specificity values of 84% and 88%.[46] Despite consensus recommendations for MR spectroscopy acquisition[52] and post-processing[53] the technique remains limited by its susceptibility to signal contamination, particularly in lesions adjacent to the ventricular system, skull, or surgical clips.

Downloaded from academic.oup.com/neuro-oncology/article/28/11/2563/8729059 by DFKZ Zentralbibliothek user on 17 November 2026

Downloaded from academic.oup.com/neuro-oncology/article/28/11/2563/8729059 by DFKZ Zentralbibliothek user on 17 November 2026

Given the high uptake of radiolabeled amino acids in gliomas and brain metastases, amino acid PET has been evaluated to differentiate between treatment-related changes including RN and viable tumor tissue.[54,55] The most widely used radiolabeled amino acids include [^{11}C]-methyl-L-methionine (MET), 3,4-dihydroxy-6-[^{18}F]-fluoro-L-phenylalanine (FDOPA), and O-(2-[^{18}F]-fluoroethyl)-L-tyrosine (FET). The longstanding view that their uptake is mainly facilitated by large neutral amino acid transporters of the L-type (LAT) in gliomas and brain metastases (eg, LAT1 and LAT2 subtypes) has recently been challenged for diffuse gliomas and requires further mechanistic investigation.[53]

For the differentiation of local RN from brain metastases relapse following radiosurgery, PET using FDOPA and MET have consistently demonstrated high sensitivity and specificity of approximately 80% for the correct diagnosis of brain metastasis recurrence.[56-59] Similarly, FET PET parameters derived from static and dynamic acquisition showed high sensitivity and specificity of 80%-90% for distinguishing radiation-induced changes after radiosurgery from recurrent brain metastases.[60,61] A recent meta-analysis including MET, FET, or FDOPA PET studies with almost 400 patients (who had undergone first-line treatment including radiotherapy and in whom a final diagnosis was established by histologic examination or imaging and clinical follow-up) highlighted the added clinical value of amino acid PET for differentiating treatment-related changes from brain metastases relapse. In that study, pooled sensitivity and specificity were 82% and 84%, respectively.[62]

In most of the latter mentioned studies, the distinction between radiation-induced changes and brain metastases relapse was based solely on a single amino acid PET scan. Recent developments such as the standardization of PET-based response assessment in gliomas and brain metastases (PET RANO 1.0 and PET RANO BM criteria) encourage the acquisition of longitudinal PET data, which may help to differentiate more accurately between treatment-induced changes and tumor progression.[63,64] A more recent study evaluated serial FDOPA PET scans and suggested that an unchanged uptake over a long-term follow-up (median time, 18 months) identified radiation-induced changes with a high accuracy of 94%.[41] FDOPA uptake did not change significantly in radionecrotic lesions, whereas it increased significantly over time in patients with brain metastases recurrence. Ultimately, combining advanced MRI sequences with amino acid PET imaging yields the strongest evidence for reliably distinguishing RN from tumor recurrence.[65] Nevertheless, although multiparametric imaging plays a key role in differentiating brain tumor relapse and RN, final diagnostic interpretation must be conducted on an interdisciplinary level.[66]

In terms of follow-up with MRI imaging, we recommend a follow-up interval of 6-12 weeks. In asymptomatic patients, 12 weeks between MRIs is suitable, while shorter intervals are appropriate in patients with progressive symptoms, worsening neurological deficits, increasing edema or mass effect, or other clinical concerns suggestive of clinically relevant disease progression. PET can be used to increase diagnostic confidence at baseline, but also during follow-up, to monitor response to RN treatment, or in case there is doubt as to whether or not progressive disease is present.

Pathology

Consensus statements on pathology of RN are listed in Table 2.

RN is a common finding in daily diagnostics and occurs in about 4%-30% of irradiated gliomas[22] and 5%-24% of brain metastases.[67] Most tissue specimens contain a mixture of post-treatment radiation effects (eg, reactive changes and RN) and viable tumor cells.[68,69] The gold standard to assess adverse response to treatment, tumor recurrence or malignant transformation as well as development of secondary radiation-associated neoplasms remains post-treatment biopsy.[68] However, biopsies and subtotal resections are subject to sampling bias, and small tissue specimens may not be representative, potentially missing mixed lesions containing both active tumor and radiation necrosis.

Unequivocal tumor cell identification in irradiated gliomas is hampered by the overlapping cytological features between neoplastic and reactive glial cells. Unless a viable, highly cellular process with frequent mitosis and/or tumor-specific (eg, palisading) necrosis is present, a low to moderately increased cellularity obscured by destructive changes and fulguration or squeeze artifacts may be compatible with a strong reactive gliosis, mesenchymal cell activation and residual bleeding with high restorative activity. Radiation-induced cytological atypia may affect tumor cells or residual cells including glial cells, neurons and endothelial cells. In glial cells, a bizarre nuclear pleomorphism, sometimes with bubbly appearance, and accumulation of abundant eosinophilic, occasionally vacuolated cytoplasms may be present and resemble giant cells in glioblastoma, IDH-wildtype.[68] Proliferating reactive astrocytes may even display mitotic figures. Radiation-induced vasculopathy may mimic microvascular proliferation and inadequately influence grading.[68]

In patients with brain metastasis, immunohistochemical lineage markers (eg, pancytokeratin/TTF1/GATA3/CDX2 etc. in carcinomas, HMB45/MelanA in melanoma) can be very helpful in assessing the amount of viable tumor cells and even allow to identify single residual tumor cells in necrotic tissue. In gliomas, immunohistochemical staining is of limited use for the diagnosis of radiation damage in IDH-wildtype gliomas and determination of disease activity. Glial markers (eg, GFAP, MAP-2, WT-1) can be expressed by tumor cells as well as reactive astrocytes.[70] Mutation-specific antibodies (eg, IDH1 p. R132H or H3.3 p. K27M) can be particularly useful in specific glioma types for quantifying the amount of viable tumor cells in post-therapy specimens with extensive reactive changes.[68,70] In case of a sufficient time interval, the lack of IDH1 R132H expression in tumor cells of an irradiated IDH-mutant glioma may help to identify radiation-associated secondary neoplasms.[71] The diagnostic role of frozen sections and cytological preparation in establishing the diagnosis of a glioma has been elaborated in detail.[72] However, evidence-based recommendations on the diagnostic accuracy of both techniques in the context of progressive glioma and RN are not available.[69] Moreover, the freezing procedure may introduce artifacts, for example more hyperchromatic or atypical appearing cells compared to a previously not cryo-preserved specimen or a loss of glioma-type specific features like perinuclear halos in oligodendrogliomas, as well as artificial and unspecific positivity

of immunohistochemical stainings.[69] At least part of the tissue should be formalin-fixed and paraffin-embedded without prior freezing.

Molecular analyses of liquid biopsies are promising strategies, but lack sufficient sensitivity for clinical monitoring; no clinical-grade circulating biomarker for the monitoring of glioma patients is currently available.[73,74] Recently, the complex spatial architecture of brain tissue with post-treatment changes and its discrepancies from progressive glioblastoma has also been described using spatial transcriptomics. Radionecrotic samples also contain tumor cells, but these tumor cells exhibited low *EGFR* expression even in the presence of gene amplification and did not show proliferation markers.[75]

In brain metastases, CSF analysis may detect resistance mutations but does not represent a minimally invasive way to discriminate RN.[76] Several studies in patients with glioma,[7778] MPNST[79] and metastasis[80] suggest that the histological quantification of the tumor burden and/or treatment-induced necrosis may contain prognostic information (eg, correlation with overall survival), but particular ratios or cutoff values in percentage have not been validated in larger patient cohorts and their use is currently not recommended for clinical practice. Individual morphological or molecular risk factors for radiation-induced damage and predictive parameters for a variable response to radiation treatment remain inadequately characterized.

Treatment

Consensus statements on management of RN are listed in Table 3.

Symptom management.—The clinical presentation of RN is highly variable in severity and type and depends on location, size and the extent of surrounding brain edema. Symptoms may include headache, seizures, cognitive impairment or focal neurological signs such as dysphasia, hemiparesis, or ataxia. The panel consensus (Table 4) is that symptom duration of more than 7 days and increasing severity of neurological symptoms in the presence of radiological findings suggestive of RN should trigger the initiation of treatment. Radiological signs of RN alone without clinical symptoms should not prompt initiation of pharmacological RN treatment.

Treatment options are steroids, bevacizumab and surgery, with choices depending on local availability, location of the lesion and site experience. Since RN and tumor recurrence share overlapping imaging features, clinicians must also consider that apparent radiographic worsening may reflect tumor progression, treatment-related changes, or mixed pathology. This requires multidisciplinary assessment and, in selected cases, resection/biopsy (Figure 1). Any deterioration under medical treatment should be evaluated within a broad differential diagnosis, including tumor progression.[81]

General management.—In most places in the world, starting with corticosteroids is the preferred approach, despite significant data indicating that bevacizumab is both more effective and possibly, more cost-effective.[82] The reason for this is their immediate effect on edema and easier access, their lower cost per dose and the fact that they are administered orally. Furthermore, in some countries, bevacizumab is either not approved or can only be used if steroids have failed. The starting dose of dexamethasone and the duration of treatment are not established because of the lack of prospective data and should be mainly guided by the patients' self-reported severity of symptoms and signs. Further, the extent of the radiographic burden can be considered in choosing the starting dose, although the self-reported symptomatic burden will remain the lead indication for the starting dose of dexamethasone and the duration of treatment. The panel consensus is that the dose should be the minimal dose that provides clinical and/or radiological benefit (Table 4). Overall, depending on the severity of symptoms and signs, the starting dose should be selected, low in case of minimal symptoms but higher and increased if necessary, always with rapid gradual reduction to the lowest possible steroid dose necessary.[66] A reasonable starting dose is 1.5-4 mg dexamethasone (or 8 mg in case of severe symptoms) given as a single dose in the morning for 3-5 days and gradual reduction by 2 mg every 3-5 days based on the symptomatic evaluation. Historical randomized evidence from patients with metastatic brain tumors demonstrated that lower daily dexamethasone doses (4-8 mg/day) provided comparable neurological improvement to higher-dose regimens but with significantly fewer steroid-related adverse events.[83] The lowest effective dose, typically 1.5-2 mg dexamethasone, should be continued until the first follow-up imaging and reduced or discontinued afterward in case of combined clinical and radiological benefit.[81,84] In summary, the minimum effective dose required for clinical stabilization should be identified by regular re-evaluation and gradual reduction. Fixed-dose and high-intensity schemes need to be avoided to prevent steroid toxicity overshadowing the clinical benefit.[85] Steroid tapering should primarily be guided by clinical status and particular the patient's self-reported symptom burden. While radiographic improvement is important, it cannot be used in isolation to guide or reduce the steroid dosing. Radiological changes in RN often do not fully align with symptomatic improvement, so neurological assessment becomes the primary driver of tapering. Steroid tapering should be initiated when neurological stability is confirmed.[86] Thus, an integrated clinical-radiological evaluation remains essential. Neurological deterioration with radiographic evidence of increasing edema or lesion increase during steroid therapy indicates inadequate RN control (with a differential diagnosis of progressive tumor) and may require steroid dosage increase or the addition of other treatments, such as bevacizumab. In general, corticosteroid therapy should not be prolonged. However, if extended use is unavoidable—such as when bevacizumab is unavailable or contraindicated—prophylaxis for gastritis and opportunistic infections should be considered.

Bevacizumab.—Radiological and/or clinical deterioration, or persistent neurological symptoms with corresponding radiological findings after 4 weeks of corticosteroid therapy or expected long duration of steroid treatment with associated adverse effects are often considered in clinical practice as a signal to initiate bevacizumab, even as first-line treatment. The panel voted 4 weeks as the time for switching

Downloaded from academic.oup.com/neuro-oncology/article/28/11/2563/8729059 by DFKZ Zentralbibliothek user on 17 November 2026

Downloaded from academic.oup.com/neuro-oncology/article/28/11/2563/8729059 by DFKZ Zentralbibliothek user on 17 November 2026

Table 3. Consensus statements on management of radiation necrosis

Statement	Accepted in round *n*°	% agreement
General management		
Neurological symptoms of RN trigger treatment	1	100.0%
Symptoms depend on the location and size of RN and surrounding edema. These can be focal neurological symptoms (eg, dysphasia, hemiparesis, ataxia), cognitive disturbances or headache	1	100.0%
Duration >7 days and increasing severity of neurological symptoms in presence of radiological findings suggesting RN should trigger the initiation of RN directed treatment	1	88.9%
Steroids		
The starting dose of dexamethasone and the duration of treatment is not fixed but should be the minimal dose that provides clinical and/or radiological benefit	2	100.0%
Radiographic findings alone are not sufficient to taper steroids Significant improvement of neurological symptoms in presence of radiological findings of decreased edema and improved RN suggest the tapering of steroids	1	88.2%
Worsening of neurological symptoms and imaging of deteriorating RN during steroid therapy suggest the escalation of therapy but should also prompt consideration of tumor progression in case of underlying tumor	2	93.0%
Bevacizumab		
In case of steroid dependent symptoms over 4 weeks with need of a daily dose Dexamethasone (or equivalent) of 8 mg, escalation of the RN treatment with bevacizumab should be considered	1	87.5%
Several dosing schemes of bevacizumab are being used: 5 mg/kg body weight every 2 weeks; 7.5 mg/kg body weight every 3 weeks, fixed dose of 400 mg every 2 weeks; fixed dose of 600 mg every 3 weeks - there is no evidence for a best/most appropriate dosing scheme of bevacizumab	1	87.5%
There is no definition of the radiological response after RN treatment	1	88.9%
Bevacizumab is an antibody against VEGF-A. The mode of action of Bevacizumab in RN is mainly through normalization of the blood vessel bed in the inflammatory area. Reduction of leakiness of blood vessels and normalization of the blood-brain barrier leads to decreased contrast uptake and edema	1	94.4%
The duration, interval and optimal dose of treatment for symptomatic RN with bevacizumab is currently unknown. A potential regimen is 4 three-weekly iv 5-10 mg/kg infusions	2	93.0%
Targeted agents and chemotherapy can be combined with bevacizumab, provided the potential vascular side-effects of the used targeted agents and chemotherapy are taken into consideration	2	93.0%
Bevacizumab at the dosing used for radiation necrosis is usually well tolerated, with wound healing issues and arterial hypertension as the main potential side effects. There is an increased risk on deep venous thrombosis of the lower extremities and pulmonary embolism and a small increased risk of cerebral hemorrhage or infarction	1	94.1%
The favorable prognostic factors for clinical and radiological response on bevacizumab treatment for RN have yet to be determined	1	100.0%
The recurrence rate of symptomatic RN after bevacizumab treatment, is unknown	2	100.0%
Treatment with bevacizumab can be repeated if effectiveness was observed during the first course	1	94.1%
Surgical management		
Surgery should be considered for radiation necrosis whenever deemed feasible without compromising patient safety since it provides the diagnosis and definitive treatment	2	80.0%
Laser Interstitial Thermal Therapy (LITT) can be considered an option in case of treatment-resistant radiation necrosis that either requires continued treatment with steroid or repeated cycles of bevacizumab and is not suitable for surgical resection	3	100.0%

to bevacizumab, if clinical benefit from steroids is not deemed to be satisfactory. We recognize that this time period is not based on solid data and clinical judgment as well as local access to bevacizumab and patient related factors and preferences should be taken into account for a personalized approach.

Many reports over the last 15 years have investigated the role of bevacizumab, an anti-VEGF monoclonal antibody in this setting.[37] Bevacizumab has demonstrated high radiographic and clinical response rates in steroid-refractory radionecrosis, but its reimbursement for this indication varies.

The rationale for this approach is the aforementioned effect on vascular damage, hypoxia and increased expression of hypoxia inducible factor a (HIF1a) and VEGF incriminated in the pathogenesis of RN.[87] This thinking led to its widespread use in RN without adequate published trial evidence.[88] The panel consensus is that RN treatment with bevacizumab should be considered in case of steroid dependent symptoms persisting for more than 4 weeks with need of a daily dose Dexamethasone (or equivalent) of 8 mg (Table 4).

An early randomized, placebo-controlled study including a total number of 14 patients with RN (radiological or biopsy 'proven') after irradiation for head-and-neck carcinoma,

meningioma, or low- to mid-grade glioma and progressive neurological symptoms published in 2011 by Levin et al[40] showed both radiological and clinical benefit in all patients who received bevacizumab and in none of those who received placebo. Several small reports confirmed the benefit of bevacizumab and systematic reviews, pooled analyses and meta-analyses have reviewed published data.[88] Another randomized study compared bevacizumab to corticosteroids in RN caused by radiation for nasopharyngeal cancer, showing it to be superior in terms of both radiological and clinical responses.[89] Other investigators also showed it to be a more cost-effective approach to treat RN.[82] Of note, quality of life and patient reported outcomes in most of these studies are not reported adequately. The dose of bevacizumab employed in all studies for RN treatment varies from 7.5 mg/kg every 3 weeks to doses of 3 mg/kg every 2 weeks for only 2 cycles to dosing schedules of 400 mg flat starting dose followed by 100 mg flat dose every 4 weeks.[2,90,91] The reported duration of treatment is variable, but usually brief (<3 months).[2,90,91]

Despite the paucity of data, bevacizumab is included in the treatment algorithm proposed by the International Stereotactic Radiosurgery Society (ISRS)[2] as well as several national guidelines.[66,81,92] Many open questions remain regarding the use of bevacizumab for RN. Although radiological response based on decreased edema onT2-weighted and FLAIR MR images and improvement of contrast-enhancement on gadolinium-enhanced T1-weighted MR images are mentioned in most publications, there are no clear-cut definitions of radiological response to this therapy in RN. Furthermore, there are no published data on the factors that would predict response to this treatment, but

Table 4. Research topics to be addressed in RN research

Research topics
Predictive factors
Understanding the biological mechanisms of RN
Improving diagnostic accuracy
Mitigating RN
Novel approaches to therapy
Grading of RN severity
The role of biosimilars of bevacizumab
Cost-effectiveness of first-line bevacizumab treatment of symptomatic RN in comparison to dexamethasone
Appropriate designs for clinical trials on RN

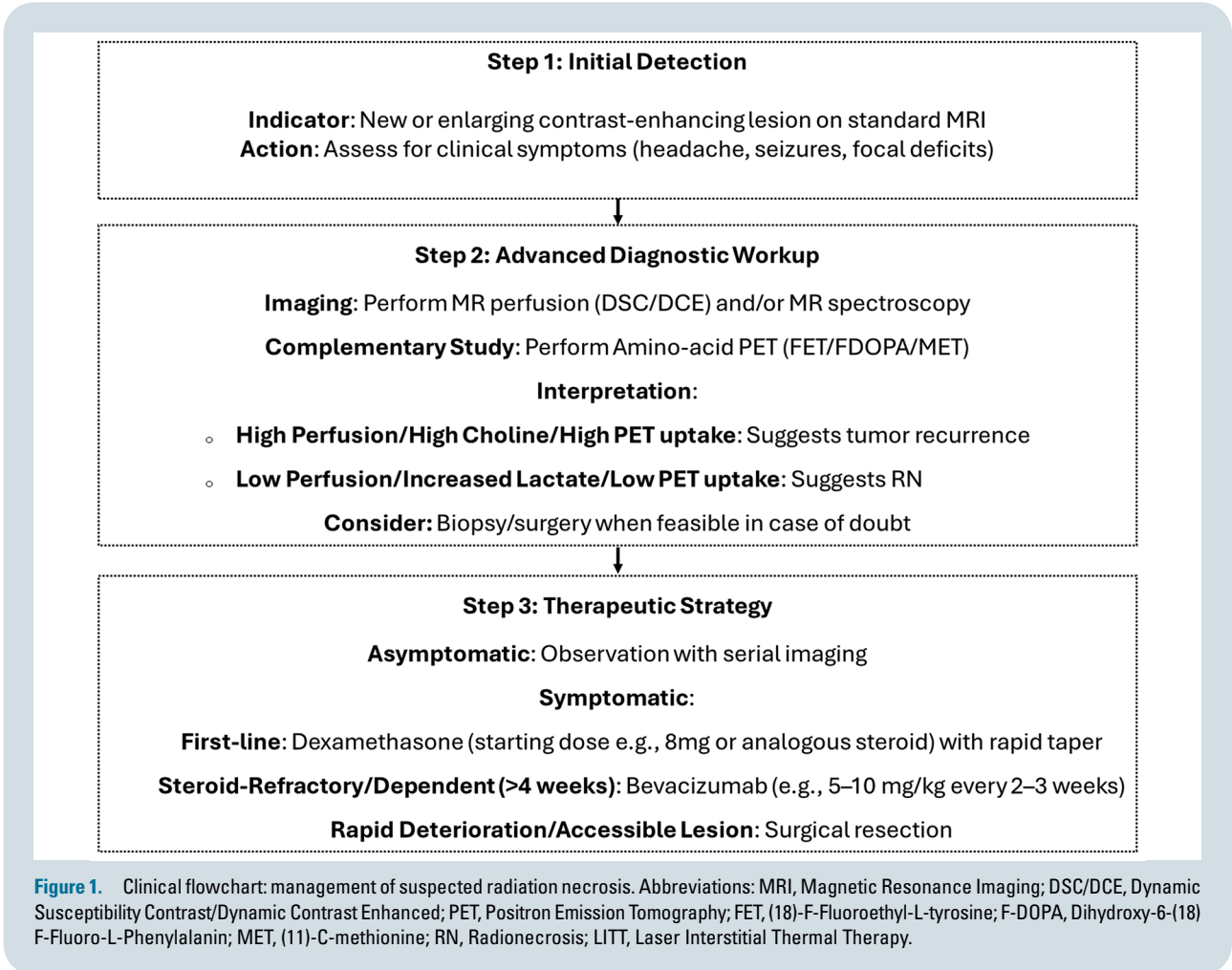

Figure 1. Clinical flowchart: management of suspected radiation necrosis. Abbreviations: MRI, Magnetic Resonance Imaging; DSC/DCE, Dynamic Susceptibility Contrast/Dynamic Contrast Enhanced; PET, Positron Emission Tomography; FET, (18)-F-Fluoroethyl-L-tyrosine; F-DOPA, Dihydroxy-6-(18) F-Fluoro-L-Phenylalanin; MET, (11)-C-methionine; RN, Radionecrosis; LITT, Laser Interstitial Thermal Therapy.

Downloaded from academic.oup.com/neuro-oncology/article/28/11/2563/8729059 by DFKZ Zentralbibliothek user on 17 November 2026

Downloaded from academic.oup.com/neuro-oncology/article/28/11/2563/8729059 by DFKZ Zentralbibliothek user on 17 November 2026

it is worthwhile noting that this is also true for steroid treatment.

Side effects of bevacizumab are well known from its use in other indications and have been reported in the studies on RN. All serious adverse events of grade ≥ 3 occurring during RN treatment are related to thromboembolic events.[85] Rates of RN recurrence after the use of bevacizumab, as well as the effects of repeated use of the agent after RN recurrence are occasionally mentioned, but there are no firm data regarding the rate of recurrence and the efficacy of retreatment.[37] As patients who developed RN are frequently using other systemic therapeutic agents for their underlying malignancies, the concurrent use of bevacizumab with these agents has not been specifically studied in the RN setting. However, bevacizumab has been given in combination with some of these agents without causing additional overlapping toxicity.[93] Importantly, bevacizumab should not be given if surgery is considered potentially the preferred option (see below).

Other Options

Boswellia Serrata is a plant extract that has been studied for its effect on radiation necrosis.[94] The proposed mechanism is decrease of cerebral edema because of anti-inflammatory action, promotion of apoptosis and inhibition of invasion. These effects are thought to be mediated via suppression of the nuclear factor κB (NFκB) and Cathepsin G by boswellic acids. Although there is limited clinical data to support its use, some centers prefer it and are increasingly gaining more experience in its use, especially as adjunct, as it was shown to decrease cerebral edema. In some types of radiation toxicity there has been experience with treatment using hyperbaric oxygen (HBO). However, in cerebral radiation necrosis there has not been enough research and data to support this approach.

Surgery

Although the evidence regarding surgical resection for RN remains limited, surgery, when safely feasible, is an effective approach for managing symptomatic RN. This is particularly the case when the location allows a safe resection, when conventional medical therapy fails, when prolonged therapy is anticipated or when neurological deterioration is rapid.[81] A surgical intervention not only allows histopathological evaluation, which is considered the gold standard in differentiating RN from tumor progression, but also typically offers immediate symptomatic relief and facilitates the successful reduction of corticosteroid dependency.[95] Cohort studies focusing on brain metastases demonstrate that surgical resection of RN in these patients leads to durable radiographic improvement. Specifically, mean perilesional T2-FLAIR edema volume decreased by 78% at 6 months postoperatively, and this reduction proved durable for up to 24 months. Steroid dependency also decreased from 54% preoperatively to 15% at 12 months postoperatively among surviving patients.[96]

Furthermore, in a single-center retrospective analysis, the extent of resection of RN was associated with long-term radiographic results: achieving gross total resection results in a significantly greater and more rapid reduction in perilesional T2-FLAIR signal volume compared to subtotal resection.[96] Another single-center cohort study showed that surgical resection resulted in a higher rate of steroid discontinuation (81.0% vs 46.7%) and reduced incidence of adverse events (3.2% vs 43.8%) compared to bevacizumab.[97] Pooled data evaluating management outcomes report symptomatic improvement or stability in 89% of patients following surgical resection.[2] An additional consideration is the risk of complications, such as compromised wound healing or hemorrhage, particularly in patients with prior treatment with steroids or bevacizumab. In patients treated with bevacizumab a 28-day washout period is recommended before safe surgery can be performed.[81,96] The panel recommends that surgical resection be considered whenever safely feasible, given its dual diagnostic and therapeutic role (agreement: 80%).

As a complementary approach, laser interstitial thermal therapy (LITT) represents a minimally invasive surgical alternative for localized RN. This method uses 1 or more stereotactically positioned probes connected to a specific laser ablation device. The procedure is then performed under MRI guidance. LITT is typically utilized for smaller lesions and has the added benefit of providing the capability to perform biopsy for pathological confirmation concurrently with the ablation procedure. Studies reviewing outcomes for patients undergoing LITT report a pooled T1 post-contrast enhancement improvement/stability rate of 88%, positioning it as a potential treatment option for symptomatic RN. These non-randomized studies suggest that efficacy of LITT may be comparable to bevacizumab in terms of radiological control, with a similar rate of adverse events (11.2% for bevacizumab and 14.9% for LITT; $P = .66$).[1,2,98,99] More studies are needed to prove the benefits of this approach. Since LITT is not available in all centers or countries and no randomized trial has been performed, its current use in the indication of RN is questionable at this stage.

Research Topics

The lack of level 1 evidence on the topic of cerebral RN diagnosis and management led us to the use of the Delphi method for the creation of this expert opinion.[3] Therefore it is of paramount importance that research is conducted in this area. A prospective randomized clinical trial comparing the clinical effects and cost-effectiveness of first-line bevacizumab versus corticosteroids in patients with symptomatic RN after focal radiotherapy of either high grade glioma or brain metastases is currently ongoing in The Netherlands ($n = 408$). Bevacizumab will be given in flat dose of 600 mg IV 3-weekly and treatment effects after 6 weeks (2 courses) will be compared with 12 weeks (4 courses) (NCT06888817).[37] Also, a large registry is ongoing by the Consortium for Intracranial Metastases Academic Research (CIMARa)[100] Several additional research topics were proposed as potential areas of interest in RN. The panel was not able to reach a consensus on the hierarchy of importance of these research topics that are listed in Table 4. A research topic that was not discussed, but gained interest after the voting is that of patient reported outcomes and lived experience with RN.

Table 5. Key points/clinical recommendations

Clinical recommendations box: key EANO consensus points
• **Diagnostic timing**: RN typically manifests **6-24 months** after radiotherapy but can appear several years later.
• **Imaging integration**: Do not rely on T1-weighted contrast-enhanced MRI alone. Highest diagnostic accuracy is achieved by combining **advanced MRI (perfusion/spectroscopy)** with **amino acid PET (FET, F-DOPA, or MET)**.
• **Histopathology gold standard**: Biopsy remains the definitive method to differentiate RN from tumor progression. In IDH-mutant gliomas, use **mutation-specific antibodies** (eg, IDH1 R132H) to identify viable tumor cells amid necrotic tissue.
• **Symptom-driven management**: Initiate treatment only for symptomatic RN (focal deficits, seizures, or cognitive decline); do not treat radiological findings alone.
• **Steroid protocol**: Use the minimum effective dose of dexamethasone. Tapering should be guided by **clinical stability** and patient-reported symptoms rather than imaging alone.
• **Bevacizumab**: Consider bevacizumab if symptoms remain steroid-dependent after **4 weeks** or if high doses (≥8 mg dexamethasone) are required or contraindicated.
• **Surgical intervention**: Pursue surgical resection (or **LITT)** for rapid symptom relief, definitive diagnosis, or when medical therapy is insufficient

Conclusion

This consensus statement relied on a structured Delphi process involving an international expert panel to establish the highest currently available level of evidence for diagnosing and managing radiation necrosis. A group of multidisciplinary experts from EANO identified areas of high concordance on the diagnosis and management of RN despite the lack of level 1 evidence. This set of agreed-upon statements may therefore serve as a guidance to clinicians, although the need for high quality clinical trials in the field remains. Key points summarizing the recommendations formulated within this manuscript are listed in Table 5. A flow chart summarizing key steps in treatment and management of RN is shown in Figure 1.

Supplementary Material

Supplementary material is available online at *Neuro-Oncology* (https://academic.oup.com/neuro-oncology).

Keywords

bevacizumab | corticosteroids | pseudoprogression | radionecrosis

Lay Summary

Radiation therapy for brain tumors sometimes leads to damage of the brain tissue itself, known as radiation necrosis. This condition causes serious symptoms and tends to look like a returning tumor on standard scans. This makes it difficult to know whether we are dealing with tumor or tissue damage. Although up to thirty percent of patients who undergo radiation therapy for brain tumors experience this problem, no universal guidelines on its diagnosis and treatment exist. To address this issue, we created an overview of current knowledge that also provides medical guidance on how to diagnose and treat this condition optimally.

Author Contributions

Johnny Duerinck: Conceptualization, Methodology, Investigation, Writing—Original draft, Writing—Review & Editing. Martin Van Den Bent: Investigation, Writing—Original draft, Writing—Review and editing. Petter Brandal: Investigation, Writing—Original draft, Writing—Review and editing. Giuseppe Minniti: Investigation, Writing—Original draft, Writing—Review and editing. Norbert Galldiks: Investigation, Writing—Original draft, Writing—Review and editing. Enrico Franceschi: Investigation, Writing—Original draft, Writing—Review and editing. Marjolein Geurts: Investigation, Writing—Original draft, Writing—Review and editing. Anna S. Berghoff: Investigation, Writing—Original draft, Writing—Review and editing. Mirjam Renovanz: Investigation, Writing—Original draft, Writing—Review and editing. Dieta Brandsma: Investigation, Writing—Original draft, Writing—Review and editing. Tom J. Snijders: Investigation, Writing—Original draft, Writing—Review and editing. Michael Weller: Investigation, Writing—Original draft, Writing—Review and editing. Susan C. Short: Investigation, Writing—Original draft, Writing—Review and editing. Michael Platten: Investigation, Writing—Original draft, Writing—Review and editing. Emilie Le Rhun: Investigation, Writing—Original draft, Writing—Review and editing. Matthias Preusser: Investigation, Writing—Original draft, Writing—Review and editing. Leonille Schweizer: Investigation, Writing—Original draft, Writing—Review and editing. Nathalie Lisa Albert: Investigation, Writing—Original draft, Writing—Review and editing. Julia Furtner: Investigation, Writing—Original draft, Writing—Review and editing. Evangelia Razis: Conceptualization, Methodology, Investigation, Writing—Original draft, Writing—Review & Editing.

Conflict of Interest Statement

J.D. has received honoraria for consultancy and advisory board participation from Servier, Miltenyi and Carthera and received clinical

Downloaded from academic.oup.com/neuro-oncology/article/28/11/2563/8729059 by DFKZ Zentralbibliothek user on 17 November 2026

Downloaded from academic.oup.com/neuro-oncology/article/28/11/2563/8729059 by DFKZ Zentralbibliothek user on 17 November 2026

trial funding from Servier. M.v.D.B. received honoraria for consultancy from Servier, Nuvation, Boehringer Ingelheim, Fore Biotherapeutics, Genenta, Incyte, Chimerix, AstraZeneca. P.B. has received honoraria for consultation or advisory board participation from Servier, GSK, Zealth, "Ekspertpanelet" and "Moloklinikken". G.M. received honoraria for lectures, consultation, or advisory board participation from Brainlab, Accuray, Servier, Astra-Zeneca, Pfizer, and Novocure. N.G. received honoraria for lectures from Servier, for advisory board participation from Telix Pharmaceuticals and Servier, and for consultancy services from Telix Pharmaceuticals. E.F. has received honoraria for advisory board participation from Genenta Science. Participated in an Incyte Steering Committee (without compensation). M.G. received honoraria for consultancy and advisory board participation from Servier, Nuvation Bio, MyTomorrows, Fore Bio and Carthera. A.S.B. has received research support from Daiichi Sankyo and Roche and honoraria for lectures, consultation, or advisory board participation from Roche, Bristol-Meyers Squibb, Merck, Daiichi Sankyo, AstraZeneca, CeCaVa, Seagen, Alexion, Servier as well as travel support from Roche, Amgen, and AbbVie. M.R. reports no conflicts of interest. D.B. has received a research grant of Gilead Sciences and honoraria for advisory board participation from Boehringer Ingelheim and Lilly Pharmaceuticals. T.J.S. reports no conflicts of interest. M.W. has received research grants from Novartis, Quercis and Versameb, and honoraria for lectures or advisory board participation or consulting from Anheart, Bayer, Curevac, Medac, Neurosense, Novartis, Novocure, Orbus, Pfizer, Philogen, Roche and Servier. S.C.S. received honoraria for consultancy from CeCaVa, Tocagen, Miltenyi, Servier, MedAc, for advisory board participation from Bayer, Chimerix and MuTomorrows and received research funding from CeCaVa. M.Pl. has received honoraria for consultancy and advisory board participation from Servier, Sun Pharma and received clinical trial funding from Servier. E.L.R. has received research grants from Bristol Meyers Squibb (BMS), and honoraria for lectures or advisory board participation or consulting from Bayer, Biodexa/Sitoxi, Janssen, Leo Pharma, Pierre Fabre, Roche, Seattle Genetics, and Servier. M.P. has received honoraria for lectures, consultation or advisory board participation from the following for-profit companies: Bayer, Bristol-Myers Squibb, Novartis, Gerson Lehrman Group (GLG), CMC Contrast, GlaxoSmithKline, Mundipharma, Roche, BMJ Journals, MedMedia, Astra Zeneca, AbbVie, Lilly, Medahead, Daiichi Sankyo, Sanofi, Merck Sharp & Dome, Tocagen, Adastra, Gan & Lee Pharmaceuticals, Janssen, Servier, Miltenyi, Böhringer-Ingelheim, Telix, Medscape, OncLive, Medac, Nerviano Medical Sciences, ITM Oncologics GmbH, AdAcAp, Crinetics. L.S. reports no conflicts of interest. N.L.A. has received honoraria for lectures, consultation or advisory board participation from ABX, Advanced Accelerator Applications, Carthera, Crinetics, ITM Oncologics, Medsir, Novartis, OncLive, Servier and Telix Pharmaceuticals, and research funding from Novocure, Servier and Telix Pharmaceuticals. J.F. has received honoraria for lectures, consultation or advisory board participation from Novarits, Seagen, Sanova, Servier. E.R. received honoraria for consultancy and advisory board participation from Servier, Astrazeneca, Novartis and Gilead and reports travel grants from AstraZeneca, Integris, Servier, Novartis, Gilead, BMS, Pfizer, Roche, Ipsen, Genekor, Karyo.

Funding

None declared.

Ethics Approval

This guideline paper utilized a Delphi consensus methodology involving a panel of international multidisciplinary experts to formulate clinical recommendations. As the research was limited to gathering expert opinions and did not involve human subjects, patient records, human tissue, or animal experiments, formal approval from an Institutional Review Board (IRB) or local Ethics Committee was not required.

Affiliations

Department of Neurosurgery, Universitair Ziekenhuis Brussel and Neuroprotection and Neuromodulation (NEUR) Research Group, Center for Neurosciences (C4N), Vrije Universiteit Brussel (VUB), Brussels, Belgium (J.D.); Department of Neurology, Brain Tumor Center, Erasmus MC Cancer Institute, Rotterdam, The Netherlands (M.V.D.B., M.G.); Department of Oncology, Oslo University Hospital, Oslo, Norway (P.B.); Institute of Clinical Medicine, University of Oslo, Oslo, Norway (P.B.); Department of Radiological Sciences, Oncology and Anatomical Pathology, Sapienza University of Rome, IRCCS Neuromed, Pozzilli (IS), Italy (G.M.); Department of Neurology, Faculty of Medicine, University Hospital Cologne, Cologne, Germany (N.G.); Institute of Neuroscience and Medicine, Research Center Juelich, Juelich, Germany (N.G.); Nervous System Medical Oncology Department, IRCCS Istituto delle Scienze Neurologiche di Bologna, Bologna, Italy (E.F.); Department of Medical Oncology, Erasmus MC Cancer Institute, Rotterdam, The Netherlands (M.G.); Division of Oncology, Department of Medicine, Medical University of Vienna, Vienna, Austria (A.S.B., M.P.); Department of Neurosurgery, University Hospital Tübingen, Eberhard Karls University Tübingen, Tübingen, Germany (M.R.); Department of Neurology and Interdisciplinary Neuro-Oncology, University Hospital Tübingen, Eberhard Karls University Tübingen, Tübingen, Germany (M.R.); Department of Neuro-Oncology, Netherlands Cancer Institute, Amsterdam, The Netherlands (D.B.); Department of Neuro-Oncology, Amsterdam University Medical Center, Amsterdam, The Netherlands (D.B.); Department of Neurology and Neurosurgery, UMC Utrecht Brain Center, University Medical Center Utrecht, Utrecht, The Netherlands (T.J.S.); Department of Neurology, University Hospital and University of Zurich, Zurich, Switzerland (M.W.); St James's Institute of Oncology, University of Leeds and Leeds Teaching Hospitals NHS Trust, Leeds, UK (S.C.S.); Department of Neurology, University Medical Center Mannheim, Heidelberg University, Heidelberg, Germany (M.P.); German Cancer Research Center (DKFZ), Heidelberg, Germany (M.P.); Department of Medical Oncology and Hematology, University Hospital Zurich, Zurich, Switzerland (E.L.R.); Institute of Neurology (Edinger Institute), University Hospital Frankfurt, Goethe University, Frankfurt am Main, Germany (L.S.); German Cancer Consortium (DKTK), Partner Site Frankfurt/Mainz, German Cancer Research Center (DKFZ), Heidelberg, Germany (L.S.); Frankfurt Cancer Institute (FCI), Frankfurt am Main, Germany (L.S.); Department of Nuclear Medicine, LMU University Hospital, Ludwig-Maximilians-Universität München, Munich, Germany (N.L.A.); Research Center for Medical Image Analysis and Artificial Intelligence (MIAAI), Faculty of Medicine and Dentistry, Danube Private University, Krems, Austria (J.F.); Third Medical Oncology Department, Hygeia Hospital, Athens, Greece (E.R.)

References

1. Gecici NN, Gurses ME, Kaye B, et al. Comparative analysis of bevacizumab and LITT for treating radiation necrosis in previously radiated CNS neoplasms: a systematic review and meta-analysis. *J Neurooncol*. 2024;168:1-11. https://doi.org/10.1007/s11060-024-04650-1
2. Vellayappan B, Lim-Fat MJ, Kotecha R, et al. A systematic review informing the management of symptomatic brain radiation necrosis after stereotactic radiosurgery and international stereotactic radiosurgery society recommendations. *Int J Radiat Oncol Biol Phys*. 2024;118:14-28. https://doi.org/10.1016/j.ijrobp.2023.07.015
3. Beiderbeck D, Frevel N, von der Gracht HA, Schmidt SL, Schweitzer VM. Preparing, conducting, and analyzing Delphi surveys: cross-disciplinary practices, new directions, and advancements. *MethodsX*. 2021;8:101401. https://doi.org/10.1016/j.mex.2021.101401
4. Taal W, Brandsma D, de Bruin HG, et al. Incidence of early pseudo-progression in a cohort of malignant glioma patients treated with chemoirradiation with temozolomide. *Cancer*. 2008;113:405-410. https://doi.org/10.1002/cncr.23562
5. Burger PC, Mahaley MS, Dudka L, Vogel FS. The morphologic effects of radiation administered therapeutically for intracranial gliomas: a postmortem study of 25 cases. *Cancer*. 1979;44:1256-1272. https://doi.org/10.1002/1097-0142(197910)44:4<1256::AID-CNCR2820440415>3.0.CO; 2-T
6. Yomo S, Oguchi K. Prospective study of 11C-methionine PET for distinguishing between recurrent brain metastases and radiation necrosis: limitations of diagnostic accuracy and long-term results of salvage treatment. *BMC Cancer*. 2017;17:713. https://doi.org/10.1186/s12885-017-3702-x
7. Giantini-Larsen A, Abou-Mrad Z, Goldberg JL, et al. Postradiosurgery cystic degeneration in brain metastases causing delayed and potentially severe sequelae: systematic review and illustrative cases. *J Neurosurg Case Lessons*. 2023;5. https://doi.org/10.3171/CASE22462
8. Nordal RA, Wong CS. Molecular targets in radiation-induced blood-brain barrier disruption. *Int J Radiat Oncol Biol Phys*. 2005;62:279-287. https://doi.org/10.1016/j.ijrobp.2005.01.039
9. Nordal RA, Nagy A, Pintilie M, Wong CS. Hypoxia and hypoxia-inducible factor-1 target genes in central nervous system radiation injury: a role for vascular endothelial growth factor. *Clin Cancer Res*. 2004;10:3342-3353. https://doi.org/10.1158/1078-0432.CCR-03-0426
10. Nonoguchi N, Miyatake SI, Fukumoto M, et al. The distribution of vascular endothelial growth factor-producing cells in clinical radiation necrosis of the brain: pathological consideration of their potential roles. *J Neurooncol*. 2011;105:423-431. https://doi.org/10.1007/s11060-011-0610-9
11. Miyata T, Toho T, Nonoguchi N, et al. The roles of platelet-derived growth factors and their receptors in brain radiation necrosis. *Radiat Oncol*. 2014;9:51. https://doi.org/10.1186/1748-717X-9-51
12. Kyrkanides S, Olschowka JA, Williams JP, Hansen JT, O'Banion MK. TNF alpha and IL-1beta mediate intercellular adhesion molecule-1 induction via microglia-astrocyte interaction in CNS radiation injury. *J Neuroimmunol*. 1999;95:95-106. https://doi.org/10.1016/s0165-5728(98)00270-7
13. Kyrkanides S, Moore AH, Olschowka JA, et al. Cyclooxygenase-2 modulates brain inflammation-related gene expression in central nervous system radiation injury. *Brain Res Mol Brain Res*. 2002;104:159-169. https://doi.org/10.1016/s0169-328x(02)00353-4
14. Moravan MJ, Olschowka JA, Williams JP, O'Banion MK. Cranial irradiation leads to acute and persistent neuroinflammation with delayed increases in T-cell infiltration and CD11c expression in C57BL/6 mouse brain. *Radiat Res*. 2011;176:459-473. https://doi.org/10.1667/rr2587.1
15. Daigle JL, Hong JH, Chiang CS, McBride WH. The role of tumor necrosis factor signaling pathways in the response of murine brain to irradiation. *Cancer Res*. 2001;61:8859-8865.
16. Aizer AA, Lamba N, Ahluwalia MS, et al. Brain metastases: a Society for Neuro-Oncology (SNO) consensus review on current management and future directions. *Neuro Oncol*. 2022;24:1613-1646. https://doi.org/10.1093/neuonc/noac118
17. Shaw E, Scott C, Souhami L, et al. Single dose radiosurgical treatment of recurrent previously irradiated primary brain tumors and brain metastases: final report of RTOG protocol 90-05. *Int J Radiat Oncol Biol Phys*. 2000;47:291-298. https://doi.org/10.1016/s0360-3016(99)00507-6
18. Winter SF, Loebel F, Loeffler J, et al. Treatment-induced brain tissue necrosis: a clinical challenge in neuro-oncology. *Neuro Oncol*. 2019;21:1118-1130. https://doi.org/10.1093/neuonc/noz048
19. Lawrence YR, Li XA, el Naqa I, et al. Radiation dose-volume effects in the brain. *Int J Radiat Oncol Biol Phys*. 2010;76:S20-S27. https://doi.org/10.1016/j.ijrobp.2009.02.091
20. Mayo ZS, Billena C, Suh JH, Lo SS, Chao ST. The dilemma of radiation necrosis from diagnosis to treatment in the management of brain metastases. *Neuro Oncol*. 2024;26:S56-S65. https://doi.org/10.1093/neuonc/noad188
21. Brandsma D, van den Bent MJ. Pseudoprogression and pseudoresponse in the treatment of gliomas. *Curr Opin Neurol*. 2009;22:633-638. https://doi.org/10.1097/WCO.0b013e328332363e
22. Ruben JD, Dally M, Bailey M, Smith R, McLean CA, Fedele P. Cerebral radiation necrosis: incidence, outcomes, and risk factors with emphasis on radiation parameters and chemotherapy. *Int J Radiat Oncol Biol Phys*. 2006;65:499-508. https://doi.org/10.1016/j.ijrobp.2005.12.002
23. Milano MT, Grimm J, Niemierko A, et al. Single- and multifraction stereotactic radiosurgery dose/volume tolerances of the brain. *Int J Radiat Oncol Biol Phys*. 2021;110:68-86. https://doi.org/10.1016/j.ijrobp.2020.08.013
24. Minniti G, Clarke E, Lanzetta G, et al. Stereotactic radiosurgery for brain metastases: analysis of outcome and risk of brain radionecrosis. *Radiat Oncol*. 2011;6:48. https://doi.org/10.1186/1748-717X-6-48
25. Lehrer EJ, Peterson JL, Zaorsky NG, et al. Single versus multifraction stereotactic radiosurgery for large brain metastases: an international meta-analysis of 24 trials. *Int J Radiat Oncol Biol Phys*. 2019;103:618-630. https://doi.org/10.1016/j.ijrobp.2018.10.038
26. Eekers DBP, Zegers CML, Ahmed KA, et al. Controversies in neuro-oncology: focal proton versus photon radiation therapy for adult brain tumors. *Neurooncol Pract*. 2024;11:369-382. https://doi.org/10.1093/nop/npae040
27. Lehrer EJ, Prabhu AV, Sindhu KK, et al. Proton and heavy particle intracranial radiosurgery. *Biomedicines*. 2021;9:31. https://doi.org/10.3390/biomedicines9010031
28. Lambrecht M, Eekers DBP, Alapetite C, et al.; work package 1 of the taskforce "European Particle Therapy Network" of ESTRO. Radiation dose constraints for organs at risk in neuro-oncology; the European Particle Therapy Network consensus. *Radiother Oncol*. 2018;128:26-36. https://doi.org/10.1016/j.radonc.2018.05.001
29. Minniti G, Niyazi M, Alongi F, Navarria P, Belka C. Current status and recent advances in reirradiation of glioblastoma. *Radiat Oncol*. 2021;16:36. https://doi.org/10.1186/s13014-021-01767-9
30. van Aken ESM, Gandhi AK, O'Cathail SM, et al. ESMO-ESTRO consensus statements on the safety of combining radiotherapy with CDK4/6, HER2, PARP, or mTOR inhibitors. *Radiother Oncol*. 2026;215:111330. https://doi.org/10.1016/j.radonc.2025.111330
31. van Aken ESM, Devnani B, Prelaj A, et al. ESMO-ESTRO consensus statements on the safety of combining radiotherapy with immune checkpoint inhibitors, VEGF(R) inhibitors, or multitargeted tyrosine kinase inhibitors. *Ann Oncol*. 2026;37:17-32. https://doi.org/10.1016/j.annonc.2025.09.008
32. Martin AM, Cagney DN, Catalano PJ, et al. Immunotherapy and symptomatic radiation necrosis in patients with brain metastases treated with

Downloaded from academic.oup.com/neuro-oncology/article/28/11/2563/8729059 by DFKZ Zentralbibliothek user on 17 November 2026

stereotactic radiation. *JAMA Oncol*. 2018;4:1123-1124. https://doi.org/10.1001/jamaoncol.2017.3993

33. Lebow ES, Pike LRG, Seidman AD, Moss N, Beal K, Yu Y. Symptomatic necrosis with Antibody-Drug conjugates and concurrent stereotactic radiotherapy for brain metastases. *JAMA Oncol*. 2023;9:1729-1733. https://doi.org/10.1001/jamaoncol.2023.4492

34. Vaios EJ, Shenker RF, Hendrickson PG, et al. Symptomatic necrosis with dual immune-checkpoint inhibition and radiosurgery for brain metastases. *JAMA Netw Open*. 2025;8:e254347. https://doi.org/10.1001/jamanetworkopen.2025.4347

35. Kossmann MRP, Ehret F, Roohani S, et al. Histopathologically confirmed radiation-induced damage of the brain - an in-depth analysis of radiation parameters and spatio-temporal occurrence. *Radiat Oncol*. 2023;18:198. https://doi.org/10.1186/s13014-023-02385-3

36. Winter SF, Vaios EJ, Muzikansky A, et al. Defining treatment-related adverse effects in patients with glioma: distinctive features of pseudoprogression and treatment-induced necrosis. *Oncologist*. 2020;25:e1221-e1232. https://doi.org/10.1634/theoncologist.2020-0085

37. Kroon LL, Dieleman EMT, Keil VC, et al. Bevacizumab for symptomatic cerebral radiation necrosis after radiation of high-grade glioma or brain metastases - when and for whom? *Neurooncol Pract*. 2025;12:747-762. https://doi.org/10.1093/nop/npaf059

38. Salans M, Ni L, Morin O, et al. Adverse radiation effect versus tumor progression following stereotactic radiosurgery for brain metastases: implications of radiologic uncertainty. *J Neurooncol*. 2024;166:535-546. https://doi.org/10.1007/s11060-024-04578-6

39. Law M. Advanced imaging techniques in brain tumors. *Cancer Imaging*. 2009;9:S4-S9. https://doi.org/10.1102/1470-7330.2009.9002

40. Levin VA, Bidaut L, Hou P, et al. Randomized double-blind placebo-controlled trial of bevacizumab therapy for radiation necrosis of the central nervous system. *Int J Radiat Oncol Biol Phys*. 2011;79:1487-1495. https://doi.org/10.1016/j.ijrobp.2009.12.061

41. Cicone F, Carideo L, Scaringi C, et al. Long-term metabolic evolution of brain metastases with suspected radiation necrosis following stereotactic radiosurgery: longitudinal assessment by F-DOPA PET. *Neuro Oncol*. 2021;23:1024-1034. https://doi.org/10.1093/neuonc/noaa239

42. Wen PY, Macdonald DR, Reardon D A, et al. Updated response assessment criteria for high-grade gliomas: response assessment in neuro-oncology working group. *J Clin Oncol*. 2010;28:1963-1972. https://doi.org/10.1200/JCO.2009.26.3541

43. Wen PY, van den Bent M, Youssef G, et al. RANO 2.0: update to the response assessment in neuro-oncology criteria for high- and low-grade gliomas in adults. *J Clin Oncol*. 2023;41:5187-5199. https://doi.org/10.1200/JCO.23.01059

44. Dhermain FG, Hau P, Lanfermann H, Jacobs AH, van den Bent MJ. Advanced MRI and PET imaging for assessment of treatment response in patients with gliomas. *Lancet Neurol*. 2010;9:906-920. https://doi.org/10.1016/S1474-4422(10)70181-2

45. van Dijken BRJ, van Laar PJ, Holtman GA, van der Hoorn A. Diagnostic accuracy of magnetic resonance imaging techniques for treatment response evaluation in patients with high-grade glioma, a systematic review and meta-analysis. *Eur Radiol*. 2017;27:4129-4144. https://doi.org/10.1007/s00330-017-4789-9

46. Teunissen WHT, Govaerts CW, Kramer MCA, et al. Diagnostic accuracy of MRI techniques for treatment response evaluation in patients with brain metastasis: asystemic review and meta-analysis. *Radiother Oncol*. 2022;177:121-133. https://doi.org/10.1016/j.radonc.2022.10.026

47. Ivanidze J, Shih RY, Utukuri PS, et al.; Expert Panel on Neurological Imaging. ACR appropriateness criteria® brain tumors. *J Am Coll Radiol*. 2025;22:S108-S135. https://doi.org/10.1016/j.jacr.2025.02.036

48. Boxerman JL, Quarles CC, Hu LS. Jumstarting brain tumor drug developement coalition imaging standardization steering committee. Consensus recommendation for a dynamic susceptibility contrast MRI protocol for use in high-grade gliomas. *Neuro Oncol*. 2020;22:1262-1275.

49. Hu LS, Eschbacher JM, Dueck AC. Correlations between perfusion MR imaging cerebral blood volume, microvelles quantification, and clinicla outcome using stereotactic analysis in recurrent high-grade glioma. *AJNR*. 2012;22:69-76.

50. Patel P, Baradaran H, Delgado D, et al. MR perfusion-weighted imaging in the evaluation of high-grade gliomas after treatment: a systematic review and meta-analysis. *Neuro Oncol*. 2017;19:118-127. https://doi.org/10.1093/neuonc/now148

51. Zhang H, Ma L, Wang Q, Zheng X, Wu C, Xu BN. Role of magnetic resonance spectroscopy for the differentiation of recurrent glioma from radiation necrosis: a systematic review and meta-analysis. *Eur J Radiol*. 2014;83:2181-2189. https://doi.org/10.1016/j.ejrad.2014.09.018

52. Wilson M, Andronesi O, Barker PB, et al. Methodological consensus on clinical proton MRS of the brain: review and recommendations. *Magn Reson Med*. 2019;82:527-550. https://doi.org/10.1002/mrm.27742

53. Lin A, Andronesi O, Bogner W, et al.; Experts' Working Group on Reporting Standards for MR Spectroscopy. Experts' working group on reporting standards for MR spectroscopy. Minimum reporting standards for in vivo magnetic resonance spectroscopy (MRSinMRS): experts' consensus recommendations. *NMR Biomed*. 2021;34:e4484. https://doi.org/10.1002/nbm.4484

54. Galldiks N, Niyazi M, Grosu AL, et al. Contribution of PET imaging to radiotherapy planning and monitoring in glioma patients – a report of the PET/RANO group. *Neuro Oncol*. 2021;23:881-893. https://doi.org/10.1093/neuonc/noab013

55. Galldiks N, Lohmann P, Aboian M, et al. Update to the RANO working group and EANO recommendations for the clinical use of PET imaging in gliomas. *Lancet Oncol*. 2025;26:e436-e447. https://doi.org/10.1016/S1470-2045(25)00193-7

56. Terakawa Y, Tsuyuguchi N, Iwai Y, et al. Diagnostic accuracy of 11C-methionine PET for differentiation of recurrent brain tumors from radiation necrosis after radiotherapy. *J Nucl Med*. 2008;49:694-699. https://doi.org/10.2967/jnumed.107.048082

57. Minamimoto R, Saginoya T, Kondo C, et al. Differentiation of brain tumor recurrence from post-radiotherapy necrosis with 11C-methionine PET: visual assessment versus quantitative assessment. *PLoS One*. 2015;10:e0132515. https://doi.org/10.1371/journal.pone.0132515

58. Lizarraga KJ, Allen-Auerbach M, Czernin J, et al. 18F-FDOPA PET for differentiating recurrent or progressive brain metastatic tumors from late or delayed radiation injury after radiation treatment. *J Nucl Med*. 2014;55:30-36. https://doi.org/10.2967/jnumed.113.121418

59. Cicone F, Minniti G, Romano A, et al. Accuracy of F-DOPA PET and perfusion-MRI for differentiating radionecrotic from progressive brain metastases after radiosurgery. *Eur J Nucl Med Mol Imaging*. 2015;42:103-111. https://doi.org/10.1007/s00259-014-2886-4

60. Galldiks N, Stoffels G, Filss CP, et al. Role of O-(2-18F-fluoroethyl)-L-tyrosine PET for differentiation of local recurrent brain metastasis from radiation necrosis. *J Nucl Med*. 2012;53:1367-1374. https://doi.org/10.2967/jnumed.112.103325

61. Ceccon G, Lohmann P, Stoffels G, et al. Dynamic O-(2-18F-fluoroethyl)-L-tyrosine positron emission tomography differentiates brain metastasis recurrence from radiation injury after radiotherapy. *Neuro Oncol*. 2017;19:281-288.

62. Schlürmann T, Waschulzik B, Combs S, et al. Utility of amino acid PET in the differential diagnosis of recurrent brain metastases and treatment-related changes: a meta-analysis. *J Nucl Med*. 2023;64:816-821. https://doi.org/10.2967/jnumed.122.264803

Downloaded from academic.oup.com/neuro-oncology/article/28/11/2563/8729059 by DFKZ Zentralbibliothek user on 17 November 2026

63. Albert NL, Galldiks N, Ellingson BM, et al. PET-based response assessment criteria for diffuse gliomas (PET RANO 1.0): a report of the RANO group. *Lancet Oncol*. 2024;25:e29-e41. https://doi.org/10.1016/S1470-2045(23)00525-9

64. Albert NL, Galldiks N, Ellingson BM, et al. RANO criteria for response assessment of brain metastases based on amino acid PET imaging. *Nat Med*. 2025;31:1424-1430. https://doi.org/10.1038/s41591-025-03633-7

65. Stopa BM, Juhász C, Mittal S. Comparison of amino acid PET to advanced and emerging MRI techniques for neurooncology imaging: a systematic review of the recent studies. *Mol Imaging*. 2021;2021:8874078. https://doi.org/10.1155/2021/8874078

66. Bernhardt D, König L, Grosu A, et al.; Expert Panel of the German Society of Radiation Oncology (DEGRO). DEGRO practical guideline for central nervous system radiation necrosis part 1: classification and a multistep approach for diagnosis. *Strahlenther Onkol*. 2022;198:873-883. https://doi.org/10.1007/s00066-022-01994-3

67. Sharma A, Mountjoy LJ, Butterfield RJ, et al. Expanding the spectrum of radiation necrosis after stereotactic radiosurgery (SRS) for intracranial metastases from lung cancer: a retrospective review. *Am J Clin Oncol*. 2020;43:128-132. https://doi.org/10.1097/COC.0000000000000642

68. Perry A, Schmidt RE. Cancer therapy-associated CNS neuropathology: an update and review of the literature. *Acta Neuropathol*. 2006;111:197-212. https://doi.org/10.1007/s00401-005-0023-y

69. Goodman AL, Velázquez Vega JE, Glenn C, Olson JJ. Congress of neurological surgeons systematic review and evidence-based guidelines update on the role of neuropathology in the management of progressive glioblastoma in adults. *J Neurooncol*. 2022;158:179-224. https://doi.org/10.1007/s11060-022-04005-8

70. Capper D, Sahm F, Hartmann C, Meyermann R, von Deimling A, Schittenhelm J. Application of mutant IDH1 antibody to differentiate diffuse glioma from nonneoplastic central nervous system lesions and therapy-induced changes. *Am J Surg Pathol*. 2010;34:1199-1204. https://doi.org/10.1097/PAS.0b013e3181e7740d

71. López GY, Van Ziffle J, Onodera C, et al. The genetic landscape of gliomas arising after therapeutic radiation. *Acta Neuropathol*. 2019;137:139-150. https://doi.org/10.1007/s00401-018-1906-z

72. Brat DJ, Prayson RA, Ryken TC, Olson JJ. Diagnosis of malignant glioma: role of neuropathology. *J Neurooncol*. 2008;89:287-311. https://doi.org/10.1007/s11060-008-9618-1

73. Zachariah MA, Oliveira-Costa JP, Carter BS, Stott SL, Nahed BV. Blood-based biomarkers for the diagnosis and monitoring of gliomas. *Neuro Oncol*. 2018;20:1155-1161. https://doi.org/10.1093/neuonc/noy074

74. Yekula A, Muralidharan K, Rosh ZS, et al. Liquid biopsy strategies to distinguish progression from pseudoprogression and radiation necrosis in glioblastomas. *Adv Biosyst*. 2020;4:e2000029. https://doi.org/10.1002/adbi.202000029

75. Seferbekova Z, Ritter M, Rukhovich G, et al. Spatial transcriptomics characterisation of radionecrotic changes in glioblastoma patients. *Neuro Oncol*. 2026;28:1150-1162. https://doi.org/10.1093/neuonc/noag026(ag026)

76. Wessels PH, Boelens MC, Monkhorst K, Sonke GS, van den Broek D, Brandsma D. A review on genetic alterations in CNS metastases related to breast cancer treatment. Is there a role for liquid biopsies in CSF? *J Neurooncol*. 2023;162:1-13. https://doi.org/10.1007/s11060-023-04261-2

77. Forsyth PA, Kelly PJ, Cascino TL, et al. Radiation necrosis or glioma recurrence: is computer-assisted stereotactic biopsy useful? *J Neurosurg*. 1995;82:436-444. https://doi.org/10.3171/jns.1995.82.3.0436

78. Hu LS, Eschbacher JM, Heiserman JE, et al. Reevaluating the imaging definition of tumor progression: perfusion MRI quantifies recurrent glioblastoma tumor fraction, pseudoprogression, and radiation necrosis to predict survival. *Neuro Oncol*. 2012;14:919-930. https://doi.org/10.1093/neuonc/nos112

79. Shurell-Linehan E, DiPardo BJ, Elliott IA, et al. Pathologic response to neoadjuvant therapy is associated with improved long-term survival in high-risk primary localized malignant peripheral nerve sheath tumors. *Am J Clin Oncol*. 2019;42:426-431. https://doi.org/10.1097/COC.0000000000000536

80. Yoo J, Cha YJ, Park HH, et al. The extent of necrosis in brain metastases may predict subtypes of primary cancer and overall survival in patients receiving craniotomy. *Cancers (Basel)*. 2022;14:1694. https://doi.org/10.3390/cancers14071694

81. Bernhardt D, König L, Grosu AL, et al.; Expert Panel of the German Society of Radiation Oncology (DEGRO). DEGRO practical guideline for central nervous system radiation necrosis part 2: treatment. *Strahlenther Onkol*. 2022;198:971-980. https://doi.org/10.1007/s00066-022-01973-8

82. Luo S, Lai S, Wu Y, et al. Cost-effectiveness analysis of bevacizumab for cerebral radiation necrosis treatment based on real-world utility value in China. *Strahlenther Onkol*. 2024;200:805-814. https://doi.org/10.1007/s00066-024-02242-6

83. Vecht CJ, Hovestadt A, Verbiest HB, van Vliet JJ, van Putten WL. Dose-effect relationship of dexamethasone on Karnofsky performance in metastatic brain tumors: a randomized study of doses of 4, 8, and 16 mg per day. *Neurology*. 1994;44:675-680. https://doi.org/10.1212/WNL.44.4.675

84. Roth P, Pace A, Le Rhun E, et al.; ESMO Guidelines Committee. Electronic address: clinicalguidelines@esmo.org. Neurological and vascular complications of primary and secondary brain tumours: EANO-ESMO clinical practice guidelines for prophylaxis, diagnosis, treatment and follow-up. *Ann Oncol*. 2021;32:171-182. https://doi.org/10.1016/j.annonc.2020.11.003

85. Weller M, Le Rhun E, Van den Bent M, et al. Diagnosis and management of complications from the treatment of primary Central nervous system tumors in adults. *Neuro Oncol*. 2023;25:1200-1224. https://doi.org/10.1093/neuonc/noad038

86. Liao G, Khan M, Zhao Z, Arooj S, Yan M, Li X. Bevacizumab treatment of radiation-induced brain necrosis: a systematic review. *Front Oncol*. 2021;11:593449. https://doi.org/10.3389/fonc.2021.593449

87. Khan M, Zhao Z, Arooj S, Liao G. Bevacizumab for radiation necrosis following radiotherapy of brain metastatic disease: a systematic review & meta-analysis. *BMC Cancer*. 2021;21:167. https://doi.org/10.1186/s12885-021-07889-3

88. Boothe D, Young R, Yamada Y, Prager A, Chan T, Beal K. Bevacizumab as a treatment for radiation necrosis of brain metastases post stereotactic radiosurgery. *Neuro Oncol*. 2013;15:1257-1263. https://doi.org/10.1093/neuonc/not085

89. Xu Y, Rong X, Hu W, et al. Bevacizumab monotherapy reduces radiation-induced brain necrosis in nasopharyngeal carcinoma patients: a randomized controlled trial. *Int J Radiat Oncol Biol Phys*. 2018;101:1087-1095. https://doi.org/10.1016/j.ijrobp.2018.04.068

90. Weng Y, Shen J, Zhang L, et al. Low-dosage bevacizumab treatment: effect on radiation necrosis after gamma knife radiosurgery for brain metastases. *Front Surg*. 2021;8:720506. https://doi.org/10.3389/fsurg.2021.720506

91. Tijtgat J, Calliauw E, Dirven I, et al. Low-dose bevacizumab for the treatment of focal radiation necrosis of the brain (fRNB): a single-center case series. *Cancers (Basel)*. 2023;15:2560. https://doi.org/10.3390/cancers15092560

92. Bevacizumab bij radionecrose bij hersenmetastasen. Richtlijnendatabase Nederland. http://richtlijnendatabase.nl/

93. Zhang L, You Y, Liu X, Liu F, Nie K, Ji Y. Osimertinib combined with bevacizumab as the first-line treatment in non-small cell lung cancer patients with brain metastasis harboring epidermal growth factor receptor mutations. *Thorac Cancer*. 2023;14:1355-1361. https://doi.org/10.1111/1759-7714.14880

94. Kirste S, Treier M, Wehrle SJ, et al. Boswellia serrata acts on cerebral edema in patients irradiated for brain tumors: a prospective, randomized,

Downloaded from academic.oup.com/neuro-oncology/article/28/11/2563/8729059 by DFKZ Zentralbibliothek user on 17 November 2026

placebo-controlled, double-blind pilot trial: a prospective, randomized, placebo-controlled, double-blind pilot trial. *Cancer*. 2011;117:3788-3795. https://doi.org/10.1002/cncr.25945

95. Telera S, Fabi A, Pace A, et al. Radionecrosis induced by stereotactic radiosurgery of brain metastases: results of surgery and outcome of disease. *J Neurooncol*. 2013;113:313-325. https://doi.org/10.1007/s11060-013-1120-8

96. Newman WC, Goldberg J, Guadix SW, et al. The effect of surgery on radiation necrosis in irradiated brain metastases: extent of resection and long-term clinical and radiographic outcomes. *J Neurooncol*. 2021;153:507-518. https://doi.org/10.1007/s11060-021-03790-y

97. Dijkstra ME, Schouten JW, Plegt L, et al. Surgical resection or bevacizumab for treatment of radiation necrosis-associated cerebral edema in patients with brain metastases: a single center experience. *Neurooncol Adv*. 2026;8:vdag120. https://doi.org/10.1093/noajnl/vdag120

98. Palmisciano P, Haider AS, Nwagwu CD, et al. Bevacizumab vs laser interstitial thermal therapy in cerebral radiation necrosis from brain metastases: a systematic review and meta-analysis. *J Neurooncol*. 2021;154:13-23. https://doi.org/10.1007/s11060-021-03802-x

99. Ahluwalia M, Barnett GH, Deng D, et al. Laser ablation after stereotactic radiosurgery: a multicenter prospective study in patients with metastatic brain tumors and radiation necrosis. *J Neurosurg*. 2019;130:804-811. https://doi.org/10.3171/2017.11.JNS171273

100. Anders CK, Van Swearingen AED, Neman J, et al. Consortium for intracranial metastasis academic research (CIMARa): global interdisciplinary collaborations to improve outcomes of patient with brain metastases. *Neurooncol Adv*. 2025;7:vdaf049.

Downloaded from academic.oup.com/neuro-oncology/article/28/11/2563/8729059 by DFKZ Zentralbibliothek user on 17 November 2026

© The Author(s) 2026. Published by Oxford University Press on behalf of the Society for Neuro-Oncology. All rights reserved. For commercial re-use, please contact reprints@oup.com for reprints and translation rights for reprints. All other permissions can be obtained through our RightsLink service via the Permissions link on the article page on our site—for further information please contact journals.permissions@oup.com.

Neuro-Oncology 2026 28(11) 2563–2579
https://doi.org/10.1093/neuonc/noag153
Guidelines